Iranian Biomedical Journal 13 (4): 237-243 (October 2009)

Effects of Tamoxifen on Morphological and Ultrastructural Aspects of Developing Hippocampus of Rat

Maliheh Nobakht*, Nowruz Najafzadeh and Bahareh Kordestani Shargh

Dept. of Histology and Neuroscience, School of Medicine, Iran University of Medical Science, Tehran, Iran

Received 24 April 2009; revised 13 October 2009; accepted 19 October 2009

ABSTRACT

Background: Tamoxifen treatment induced cell death in the hippocampus formation of the prenatal and postnatal rat. The present study delineates the effect of tamoxifen on developing hippocampus in prenatal, postnatal and full term neonate rats received certain doses of the partial antagonist tamoxifen. **Methods:** After perfusion and fixation, the brains were removed and processed for light and electron microscopy. The morphology, ultrastructure and the density of the neurons in different ages (E22, P1, P7 and P21) and in different areas of developing hippocampus including cornu ammonis (CA1 and CA3), dentate gyrus and subiculum were studied. **Results:** These findings showed that in tamoxifen-treated groups, the cell number of pyramidal neurons of CA1 and subiculum significantly decreased comparing to control groups in E22, P1 and P7 but not in third weeks. The mitochondria of the above mentioned groups also showed a dilated feature with less cristae than control group and most of them were greatly enlarged and swollen into spherical shapes rather than the normal ovoid or rod shape. **Conclusion:** The present study shows that prenatal exposure to tamoxifen alters neurogenesis in developing rat hippocampus. These results demonstrated the non-neuroprotective roles of tamoxifen. *Iran. Biomed. J. 13 (4): 237-243, 2009*

Keywords: Developing hippocampus, Tamoxifen, Ultrastructure

INTRODUCTION

Tamoxifen is widely recognized as an estrogen antagonist because it has ability to block or attenuate estrogen-induced response in several target tissues. Anti-estrogenic effects of tamoxifen including suppression or growth in estrogen receptor-positive breast cancers [1], blocking uterine growth in rats and hamsters, and oviduct growth in chicks and quail [2] are well-documented. These findings presented that tamoxifen functions as an antagonist or agonist may be both tissue and species specific.

Estrogen also has a deep effect on structure and function of hippocampus that is accepted to play an important role in learning and memory. Interestingly, most observed effects of estrogen have been restricted to CA1 pyramidal neurons and interneurons of dorsal hippocampus, a region that contains only a few, scattered estrogen receptor-positive neurons [3-7]. To our knowledge, the non-neuroprotective role [1] of tamoxifen is mostly restricted to the certain areas of the brain and concerning different means; CA1, CA2, CA3 and dentate gyrus (DG)} areas of hippocampus. We also studied developmental effects of tamoxifen on CA1, CA3, DG and subiculum of the hippocampus of the neonate and postnatal rat. Evaluation of ultrastructural neurons in mentioned hippocampal areas including cell density and cell size was examined in the present study.

MATERIALS AND METHODS

All animal procedures were approved by the Institutional Animal Care and Use Committee (Iran University of Medical Sciences, Tehran). In the present study, 60 male and female Wistar rats (180-200 g, Hesarak Institute, Karaj) were used. The animals were individually housed in regular polyethylene cages (35 cm long, 22 cm wide and 18 cm deep) with ad libitum access to food and water in a 12:12 h light/dark vivarium and appropriate

*Corresponding Author: E-mail: manob@iums.ac.ir

[Downloaded from ibj1.pasteur.ac.ir on 2026-10-16]

[DOR: 20.1001.1.1028852.2009.13.4.3.9]

[DOI: -]

temperature. A vaginal smear from each female rat was examined daily and rats entering estrus were mated with adult males. Vaginal smears of mated females were examined on the following morning. If sperm was observed, this day was designated as Day 1 of pregnancy and the pregnant females were housed in separate cages. One day prior to labor (E21) and on the childbirth day (E22) pregnant rats received tamoxifen (250 µg i.p.) twice daily. Animals at the same gestational age were used as control. Control animals were mated similar to test rats and received equal amount of the solvent (propylene glycol). Six hours after the last injection, the brains were removed and hippocampi were isolated as described [1].

The animals were divided in three groups: sham, control and experiment. Each group was further divided into 4 following subgroups: 6 hours after the last injection of tamoxifen (E22), 16 hours after birth (P1), one week after birth (P7), and three weeks after birth (P21). Each subgroup contained 6 rats [8] and animals at the same gestational age were used as controls. The animals were deeply anesthetized with sodium pentobarbital (for mother and neonate 20 and 5 mg/kg intraperituneum, respectively). Then, they were perfused and fixed transcardially by Ringer's solution containing heparin (1 IU/ml), immediately followed by Karnovsky's solution (20-30 ml/min for 10 min). The brains of prenatal and postnatal animals were removed and processed for light and electron microscopic study.

In the light microscopic study, the brains were postfixed in Karnovsky's solution overnight, then dehydrated with increasing concentration of ethanol and finally infiltrated and embedded with paraplast. By using freezing microtome, 10 µm coronal sections were prepared. Nissl and toluidine blue staining were done for all the specimens selected for light microscopic study. The sections were observed by using an Olympus photomicroscope (PROVIS AX70, Japan) and an Olympus digital camera (DP11, Japan).

Electron microscopy was conducted for only CA1 region. After perfusion and fixation, the brains were removed and postfixed in Karnovsky's solution overnight and 2% osmium tetroxide in 0.2 M in sodium phosphate buffer was used as secondary fixative. Certain blocks (1-1.5 mm thick) of CA1 region of hippocampus were prepared, then dehydrated with increasing concentration of acetone, further washed with acetone, saturated with Epon 812, embedded in capsules, and left to polymerize.

Semithin (0.1-0.3 µm) or ultrathin (60-80 nm) sections were cut using an ultramicrotome. Semithin sections were mounted on glass slides, stained with toluidine blue and examined with light microscopy. After trimming, ultrathin sections were then mounted on copper grids, stained with uranyl acetate and lead citrate and examined with Leo 906, Zeiss, Germany electron microscopy at different magnification.

The values from each hippocampal area were considered as an individual group. Numerical densities reported are averages for all blocks in an age group with standard error of the mean. Data were analyzed using SYSTAT V 11.0 (SPSS) and analysis of independent samples t-test was performed on all groups.

RESULTS

Our study showed the following results for light and electron microscopy, respectively. Light microscopic examination showed a significant decrease in cell number on pyramidal neurons of the CA1, exposed to tamoxifen in E22, P1 and P7 but not in third week. Thus, there was a significant interaction between development and tamoxifen treatment. Tamoxifen significantly altered the number of cells on the pyramidal cell of hippocampus CA1 subregion, but not in third week. Also, neuronal density in subiculum was decreased a little such that tamoxifen treatment prevented to increase the cell number (Fig. 1).

Our findings show that the number of pyramidal neurons of CA1 and subiculum was significantly decreased in tamoxifen-treated rats in E22, P1, and P7. We found that cellular density is low in early stages of development; however, cellular density and cellular thickness gradually increased during the development particularly in the third week. Our findings also showed that tamoxifen had no effects on CA3 and DG of all trial groups. Light microscopic quantitative examination for both cresyl violet and toluidine blue staining revealed mitochondrial changes in E22, P1 and P7 but not for third week animals. Mitochondria nuclear envelope and chromatin distribution of CA1 area of the hippocampus were structurally normal in the control and sham groups (Fig. 2). Our findings also showed that in E22, there were numerous shrinkage nuclei and clumping or aggregation of chromatin distribution, and also disruption of nuclear envelope (Fig. 3).

[Downloaded from ibj1.pasteur.ac.ir on 2026-10-16]
[DOR: 20.1001.1.1028852.2009.13.4.3.9]
[DOI: -]

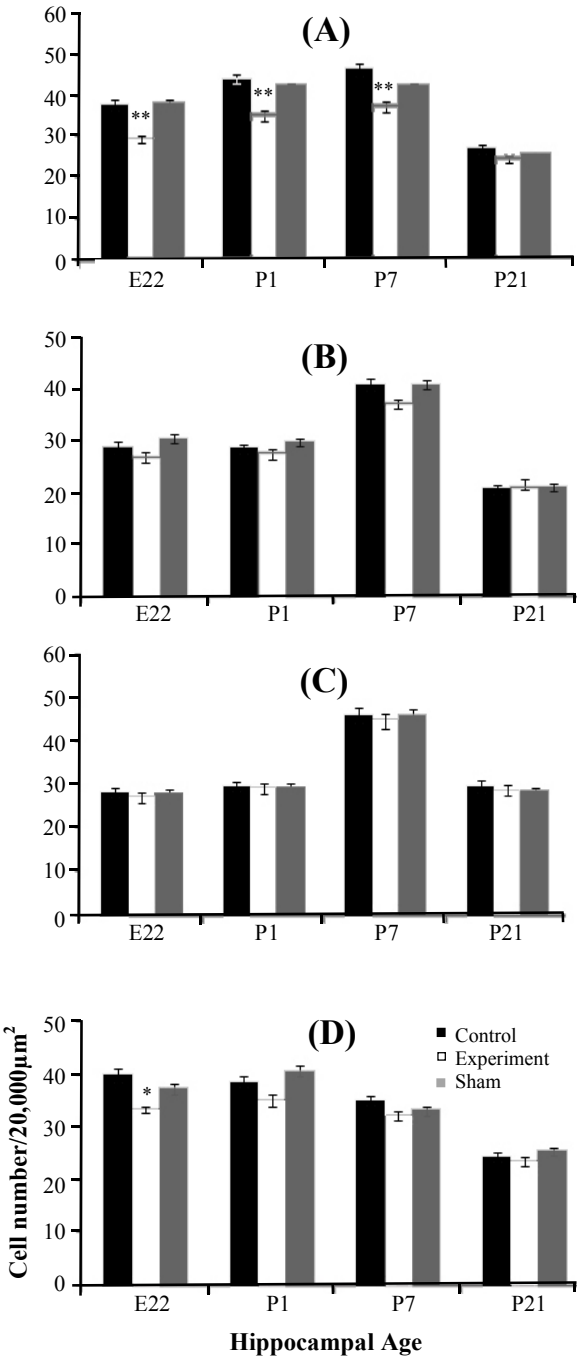

Fig. 1. Quantitative analysis of the effects of developmental stages and tamoxifen treatment on cell number. The number of cells was counted in relation to the subregion and age. **(A)** Tamoxifen significantly reduced the cell number in CA1 subregion to first week and demonstrated no effects in third week. **(B)** Tamoxifen did not alter the cell number in CA3 subregion in all ages. **(C)** Tamoxifen did not alter the cell number in D.G. subregion at either age. **(D)** Tamoxifen reduced the number of cells in subiculum to first week and demonstrated no effects on in third weeks. Data are expressed as mean ± SEM. **P*<0.05; ***P*<0.01 significantly different from Control.

In view of electron microscopy, only CA1 region of hippocampus of E22, P1 and P21 was studied. No signs of degeneration were seen in control animals and mitochondria appeared as electron-dense structure with regular cristae inside and displayed smooth membrane and condensations of nuclear chromatin. Neither cytoplasm membrane nor their

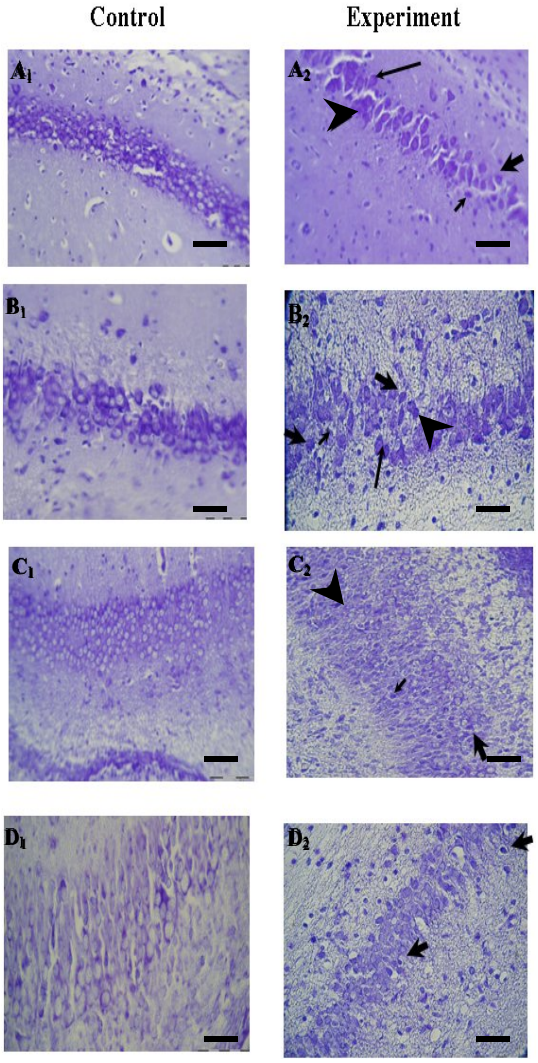

Fig. 2. Photomicrograph of Nissl staining of CA1 neurons of E22 **(A1, A2)**, P1 **(B1, B2)**, P7 **(C1, C2)**, and P21 **(D1, D2)** of control (Control) and tamoxifen-treated (Experiment) animals. In the control groups the thickness of the layers increases from E22 to P21 and neurons are being matured. In the experimental groups damaged neurons (arrowheads) are heavily stained and dense nuclei with irregular nuclear membrane (short thin arrows), nuclear shrinkage (thick arrows), and chromatin clumping (long thin arrows) are marked. P21 is the least affected area and exhibited shrunken and triangulated neuronal body with a possible lightly reaction in the immediate vicinity. Majority of neurons in P21 area are morphologically unaltered and similar in form and staining to those in the control tissue. Photomicrographs are representative of n = 8. Scale bars = 250 µm.

[Downloaded from ibj1.pasteur.ac.ir on 2026-10-16]
[DOR: 20.1001.1.1028852.2009.13.4.3.9]
[DOI: -]

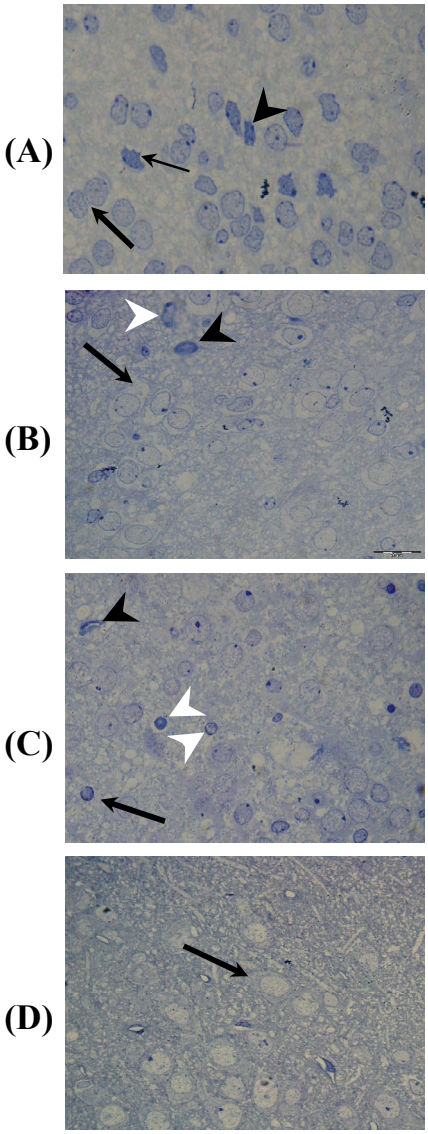

Fig. 3. Photomicrograph of semi-thin sections blue staining of CA1 neurons of E22 **(A)**, P1 **(B)**, P7 **(C)** and P21 **(D)**. (E22) shows more changes than P1 and P7. Some neurons exhibit additional heterochromatin staining. Also photograph revealed irregular nuclear membrane (thin arrow), chromatin clumping (white arrowheads) cytoplasm vacuolated (thick arrows), and dense nuclei (black arrowheads). P21 seemed to be the least affected area, this data confirm the Nissl staining studies. Scale bars = 100 µm

organelles showed any signs of morphological abnormalities. In P21 groups in compared to the sham groups animals, we observed low changes in ultrastructure (Fig. 4). In CA1 area of E22, P1 and P7, degenerated neurons were seen. Damaged cells were electron-dense with irregular shape and disruption of nuclear membrane, pyknosis and shrinkage of nucleus, condensation and clumping of chromatin in nucleus. The mitochondria of the mentioned above groups also showed dilated feature with low cristae than control group, most of them were greatly enlarged and swollen into spherical shapes rather than the normal ovoid or rod shape (Fig. 4). Less frequently, enlarged and structurally abnormal mitochondria were also founded in the CA1 region of P1. Mild degrees of spherical mitochondrial swelling occurred in P7 and to lesser extent in P21. Fewer changes were seen in the CA3 and DG.

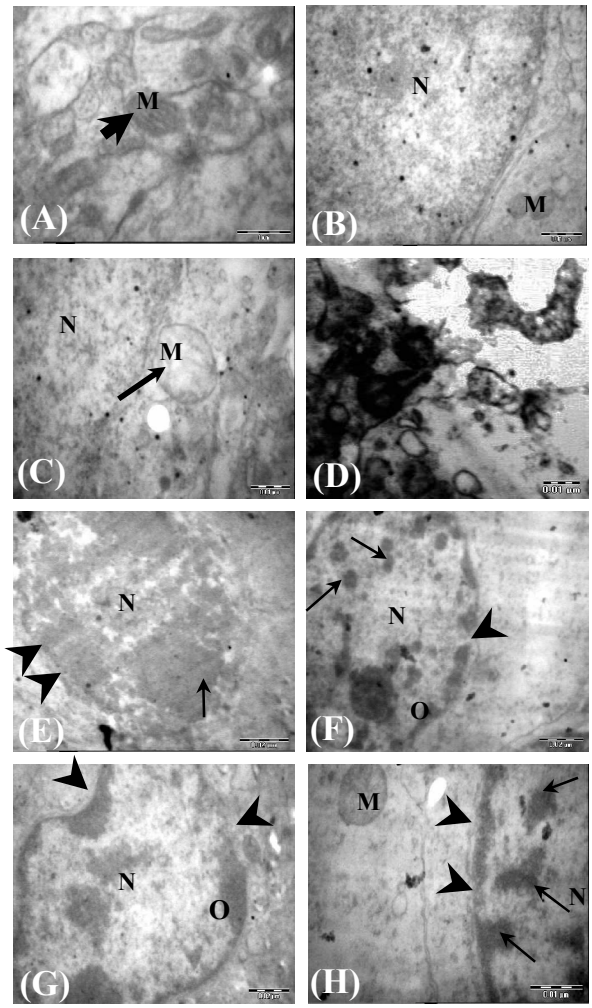

Fig. 4. Electron micrographs of CA1 hippocampal neurons of control **(A, B)**, E22 **(C, D)**, P1 **(E)**, P7 **(F, G)** and P21 **(H)**. Fragmentation with irregular nuclear membrane , disrupted nuclear membrane, nuclear shrinkages and chromatin clumping of CA1 neuron of E22, P1, P7 and P21. Neuron of CA1 region of control animals (A) have oval mitochondria (M) with regular cristae (short thick arrow), nucleus (N) with occasional condensations of nuclear chromatin (long thin arrows), but in damaged cells after tamoxifen treatment mitochondria appeared dilated (long thick arrow) and fewer cristae. Nucleus of some neurons showed clumping and marginalization (O) chromatin. Nuclear membrane shows enfolding and disruption (arrowheads). Scale bars = 50 µm.

[Downloaded from ibj1.pasteur.ac.ir on 2026-10-16]
[DOR: 20.1001.1.1028852.2009.13.4.3.9]
[DOI: -]

[Downloaded from ibj1.pasteur.ac.ir on 2026-10-16]

[DOR: 20.1001.1.1028852.2009.13.4.3.9]

[DOI: -]

DISCUSSION

Our findings indicate that tamoxifen treatment of pregnant rats could affect hippocampus formation in prenatal and postnatal rat. Based on our results, we believe that tamoxifen might be the main cause of these alterations in different areas of the hippocampus. Our results in some parts agreed with the results reported by other researchers [9, 10, 1]. The most conspicuous finding was in the nucleus and mitochondria. The nucleus in some neurons was extremely shrunken and darkened whereas in others the nucleus was clumping or contained marginated chromatin [9]. According to the literature, these cellular characteristic could be considered as apoptotic changes in CA1 region in tamoxifen treatment. Therefore, in early neonatal rat hippocampus, tamoxifen prevents to increase the number of cell. These results demonstrated the non-neuroprotective roles of tamoxifen. In addition to apoptotic cells, some other neurons showed different morphological patterns of cell death that probably reflects different stages of the cell death process [11].

Studies have indicated that tamoxifen causes significant alterations of the nucleus and mitochondria of certain central nervous system regions. The nuclei of certain neurons were extremely shrunken and darkened whereas in other neurons, nuclei were clumping and contained marginated chromatin [12, 13].

It has been shown that the decrease in cell number might be tamoxifen-dependent and any changes in the hippocampal formation may occur following manipulation in the level of estradiol and progesterone [14, 15].

It has been also reported that estrogen treatment could prevent cell death of pyramidal neurons in the CA1 region and subiculum [9-16]. Age-related changes in the number of the neurons of different regions of rat hippocampus that were shown in our study had been reported by other researchers [17-20]. It has been shown that ageing could form the number of neurons across all regions of the hippocampal formation [17, 21, 22]. There are some reports that claim the number of the neurons within CA3 region is constant throughout the life [23-25].

In addition to apoptotic cells, other neurons showed different morphological patterns of cell death that might reflect different stages of the cell death process [26, 27]. It has been reported that decrease in cell number in the hippocampus might be NOS-dependent and changes in hippocampal formation occur following alteration of the estradiol and progesterone levels [28-30].

Tamoxifen treatment also produced mitochondrial and nucleus abnormalities as seen by Pliss *et al.* [31] and Song *et al.* [32]. Moreover, it is the same for the mitochondria of CA1 neurons [33]. Studies in tamoxifen-treated animal models have also reported the enlargement of mitochondria along with disruptions of mitochondria cristae [33-35]. These changes might occur across with cell death process of the neurons [36, 37]. The results of this developmental study suggest that CA1 region in hippocampus is much sensitive to tamoxifen because, our results revealed the morphological and ultrastructural changes in this area.

ACKNOWLEDGEMENTS

The authors are grateful to Ms. F. Mohammad-zadeh for her technical assistance. Also, the authors would like to appreciate Cellular and Molecular Research Center of Iran University of Medical Sciences for support and assistance.

REFERENCES

1. Silva, I., Mello, L.E.A.M., Freymuller, E., Haidar, M.A. and Edmund, B.C. (2000) Estrogen, progestogen and tamoxifen increase synaptic density of the hippocampus of ovariectomized rats. *Neurosci. Lett. 291 (3): 183-186*.
2. Luine, V.N., and McEwen, B.S. (1977) Effects of stradiol on turnover of type-A monoamine-oxidase in brain. *J. Neurochem., 28: 1221-1227.*
3. Shughrue, P.J. and Merchenthaler, I. (2003) Estrogen prevents the loss of CA1 hippocampal neurons in gerbils after ischemic injury. *Neuroscience 116 (3): 851-861.*
4. Shughrue, P.J., and Merchenthaler, I. (2001) Distribution of estrogen receptor β immunoreactivity in the rat central nervous system. *J. Comp. Neurol. 436: 64-81*.
5. Shughrue, P.J. and Merchenthaler, I. (2000) Evidence for novel estrogen binding sites in the rat hippocampus. *Neuroscience 99 (4): 605-612*.
6. Shughrue, P.J., Lane, M.V. and Merchenthaler, I. (1997) Comparative distribution of estrogen receptor-α and β mRNAs in the rat central nervous system. *J. Comp. Neurol. 388: 507-525*.
7. Weiland, N.G., Orikasa, C., Hayashi, S. and McEwen, B.S. (1997) Distribution and hormone regulation of estrogen receptor immunoreactive cells in the hippocampus of male and female rats. *J. Comp.*

Neurol. 388 (4): 603-612.

8. Weiner, C.P., Lizasoain, I., Baylis, S.A., Knowles, R.G., Charles, I.G. and Moncada, S. (1994) Induction of calcium-dependent nitric oxide synthases by sex hormones. *Proc. Natl. Acad. Sci. USA 91 (11): 5212-5216.*
9. Islam, A., Westman, J., Bogdanovic, N., Suliman, I.A., Lindell, I., Winblad, B. and Adem, A. (1999) Ultrastructural analysis of the hippocampus of adult rats after long-term adrenalectomy. *Brain Res. 849 (1-2): 226-230.*
10. MacGregor, J.I. and Jordan, V.C. (1998) Basic guide to the mechanisms of anti-estrogen action. *Pharmacol. Rev. 50 (2): 151-196.*
11. Wilcox, B.J., Applegate, M.D., Portera-Cailliau, C. and Koliatsos, V.E. (1995) Nerve growth factor prevents apoptotic cell death in injured central cholinergic neurons. *J. Comp. Neurol. 395 (4): 573-585.*
12. Parihar, A., Parihar, M.S. and Ghafourifar, P. (2008) Significance of mitochondrial calcium and nitric oxide for apoptosis of human breast cancer cells induced by tamoxifen and etoposide. *Int. J. Mol. Med. 21 (3): 317-324.*
13. Satake, A., Takaoka, M., Nishikawa, M., Yuba, M., Shibata, Y., Okumura, K., Kitano, K., Tsutsui, H., Fujii, K., Kobuchi, S., Ohkita, M. and Matsumura, Y. (2008) Protective effect of 17beta-estradiol on ischemic acute renal failure through the PI3K/Akt/eNOS pathway. *Kidney Int. 73 (3): 308-317*
14. Weiland, N.G. and Orchinik, M. (1995) Specific subunit mRNAs of the GABAA receptor are regulated by progesterone in subfields of the hippocampus. *Brain Res. Mol. Brain Res. 32 (2): 271-278.*
15. Weiland, N.G. (1992) Glutamic acid decarboxylase messenger ribonucleic acid is regulated by estradiol and progesterone in the hippocampus. *Endocrinology 131: 2697-2702.*
16. Pinnock, S.B., Balendra, R., Chan, M., Hunt, L.T., Turner-Stokes, T. and Herbert, J. (2007) Interactions between nitric oxide and corticosterone in the regulation of progenitor cell proliferation in the dentate gyrus of the adult rat. *Neuropsychopharmacology 32 (2) : 493-504.*
17. Devaney, K.O. and Johnson, H.A. (1984) Changes in cell density within the human hippocampal formation as a function of age. *Gerontology 30 (2): 100-108.*
18. Geinisman, Y., Detoledo-Morrell, L., Morrell, F. and Heller, RE. (1995) Hippocampal markers of age-related memory dysfunction; behavioral, electrophysiological and morphological perspectives. *Prog. Neurobiol. 45 (3): 223-252.*
19. Sapolsky, R.M., Kery, L.C. and McEwen, B.S. (1985) Prolonged glucocorticoid exposure reduces hippocampal neuron number: implication for aging. *J. Neurosci. 5: 1222-1227.*
20. Poe, B.H., Linville, C., Riddle, D.R., Sonntag, W.E. and Brunso-Bechtold, J.K. (2001) Effects of age and insulin-like growth factor-1 on neuron and synapse number in area CA3 of hippocampus. *Neuroscience 107 (2): 231-238.*
21. Meaney, M.J., Aitken, D.H., Bahatnagar, S. and Sapolsky, R.M. (1991) Postnatal handling attenuates certain neuroendocrine, anatomical, and cognitive dysfunctions associated with aging in female rats. *Neurobiol. Aging 12 (1): 31-38.*
22. Peters, A., Rosene, D.L., Moss, M.B., Kemper, T.L., Abraham, C.R., Tigges, J. and Albert, M.S. (1996) Neurobiological bases of age-related cognitive decline in the rhesus monkey. *J. Neuropathol. Exp. Neurol. 55 (8): 861-874.*
23. Curcio, C.A., and Hinds, J.W. (1983) Stability of synaptic density and spine volume in dentate gyrus of aged rats. *Neurobiol. Aging 4 (1): 77-87.*
24. Kadar, T., Silbermann, M., Brandeis, R. and Levy, A. (1990) Age-related structural changes in the rat hippocampus: correlation with working memory deficiency. *Brain Res. 512 (1): 113-120.*
25. Landfield, P.W., Braun, L.D., Pitler, T.A., Lindsey, J.D. and Lynch, G. (1981) Hippocampal aging in rats: a morphometric study of multiple variables in semi-thin sections. *Neurobiol. Aging 2 (4): 265-275.*
26. Wilcox, B.J., Applegate, M.D., Portera-Caillau, C. and Koliatsos, V.E. (1995) Nerve growth factor prevents apoptotic cell death in injured central cholinergic neurons. *J. Comp. Neurol. 395 (4) : 573-585.*
27. Shughrue, P.J. and Merchenthaler, I. (1999) Evidence for novel estrogen binding sites in the rat hippocampus. *Neuroscience 99 (4): 605-612.*
28. Veenman, C.L., Lehmann, J., Stöhr, T., Totterdell, S., Yee, B., Mura, A. and Feldon, J. (1999) Comparisons of the densities of NADPHD reactive and nNOS immunopositive neurons in the hippocampus of three age groups of young non-handled and handled rats. *Dev. Brain Res. 114 (2): 229-243.*
29. Zhou, Q.G., Hu, Y., Hua, Y., Hu, M., Luo, C.X., Han, X., Zhu, X.J., Wang, B., Xu, J.S. and Zhu, D.Y. (2007) Neuronal nitric oxide synthase contributes to chronic stress-induced depression by suppressing hippocampal neurogenesis. *J. Neurochem. 103 : 1843–1854.*
30. Nobakht, M. , Fattahi, M., Samadi, M., Tabatabaei, P. and Majidzadeh, S. (2007) Expression of neuronal nitric oxide synthase during embryonic development of the rat optic vesicle. *Pakistan J. Biol. Sci. 10 (7): 1078-1082.*
31. Pliss, L. Balcar, V.J., Bubenikova, V., Pokorny, J., Fitzgibbon, T. and Stastny, F. (2003) Morphology and ultrastructure of rat hippocampal formation after I.C.V. administration of n-Acetyl-L-Aspartyl-L-Glutamate. *Neuroscience 122 (1): 93-101.*

[Downloaded from ibj1.pasteur.ac.ir on 2026-10-16]
[DOR: 20.1001.1.1028852.2009.13.4.3.9]
[DOI: -]

32. Song, D.D., Shults, C.W., Sisk, S.A., Rockenstein, E. and Masliah, E. (2004) Enhanced substantia nigra mitochondrial pathology in human α-synuclein transgenic mice after treatment with MPTP. *Exp. Neurol. 186 (2): 158-172.*
33. Wise, P.M., Dubal, D.B., Wilson, M.E., Rau, S.W. and Bottner, M. (2001) Mini review: neuroprotection effects of estrogen- new insights into mechanisms of actions. *Endocrinology. 142 (3): 969-973.*
34. Galceran, J., Miyashita-Lin, E.M., Devaney, E., Rubenstein, J.L. and Grosschedi, R. (2000) Hippocampus development and generation of dentate gyrus granule cells is regulated by LEF1. *Development 127 (3): 469-482.*
35. Wood, G.E., Young, L.T., Reagan, L.P., Chen, B. and McEwen, B.S. (2004) Stress-induced structural remodeling in hippocampus: Prevention by lithium treatment. *Proc. Natl. Acad. Sci. USA 101 (11): 3973-3978.*
36. Anglade, P., Vyas, S., Javoy-Agid, F., Herrero, M.T., Michel, P.P., Marques, J., Mouatt-Prigent, A., Ruberg, M., Hirsch, E.C. and Agid, Y. (1997) Apoptosis and autophagy in nigra neurons of patients with Parkinson's disease. *Histol. Histopathol. 12 (1): 25-31.*
37. Clarke, P.G.H. (1990) Developmental cell death: morphological diversity and multiple mechanisms. *Anat. Embryol (Berl). 181 (3): 195-213.*

[Downloaded from ibj1.pasteur.ac.ir on 2026-10-16]

[DOR: 20.1001.1.1028852.2009.13.4.3.9]

[DOI: -]