FULL LENGTH	Iranian Biomedical Journal 30 (2 & 3): 132-140 March & May 2026

Therapeutic Effects of *Vernonia amygdalina* on Oxidative Stress and Histopathological Damage in Pancreatic Toxicity Induced by 1,2-dimethylhydrazine in Wistar Rats

Augustine O. Okpiabhele[1*], Osahon D. Abu[2], Ambrose E. Akpovona[1]

[1]Department of Biochemistry, Faculty of Natural and Applied Sciences, Michael and Cecilia Ibru University, Ughelli, Delta State, Nigeria; [2]Department of Biochemistry, Faculty of Life Sciences, University of Benin, Benin City, Edo State, Nigeria

OPEN ACCESS

Article type: Research Article
Received: November 22, 2025
Revised: April 15, 2026
Accepted: April 27, 2026
Published online: April 29, 2026

How to cite:
Okpiabhele AO, Abu OD, Akpovona AE. Therapeutic Effects of *Vernonia amygdalina* on Oxidative Stress and Histopathological Damage in Pancreatic Toxicity Induced by 1,2-dimethylhydrazine in Wistar Rats. *Iran. Biomed. J.* 2026; 30 (2 & 3): 132-140.

This article is licensed under a Creative Commons Attribution-NonDerivatives 4.0 International License.

ABSTRACT

Background: 1,2-Dimethylhydrazine (DMH) induces pancreatic oxidative stress via reactive oxygen species overproduction and antioxidant depletion. Given the rich phytochemical and antioxidant properties of *Vernonia amygdalina*, this study investigated its therapeutic effects in inhibiting oxidative stress and histopathological damage induced by DMH in Wistar rats.

Methods: Adult male Wistar rats were divided into different groups and exposed to DMH via the intraperitoneal route. Animals received oral administration of *V. amygdalina* ethanol extract at low (200 mg/kg) and high (400 mg/kg) doses, both before and after DMH exposure. The pancreatic tissues were then subjected to biochemical analysis and histopathological examination using standardized protocols.

Results: The administration of *V. amygdalina* significantly attenuated body weight loss in both the pre- and post-treatment groups. Furthermore, it significantly improved ($p < 0.05$) the levels of total protein, amylase, nitric oxide, catalase, superoxide dismutase, malondialdehyde, glutathione peroxidase, glutathione (GSH), and glutathione reductase and reduced GSH percentages compared to the DMH group. The pancreatic tissues from DMH-induced rats treated with *V. amygdalina* showed a significant reduction ($p < 0.05$) in organ weight compared to the DMH group. Histological studies revealed the protective and regenerative effects of *V. amygdalina* on pancreatic tissues.

Conclusion: This study indicates that *V. amygdalina* can effectively suppress irregularities in pancreatic function and oxidative stress induced by DMH toxicity due to its antioxidant properties. This observation implies that *V. amygdalina* holds promise as a novel therapeutic strategy for improving DMH systemic toxicity in animal models and could serve as a benchmark for future clinical trials. ***DOI: 10.22034/IBJ.30.3.132***

Keywords: Antioxidants, Pancreas, Toxicity

Corresponding Author: Augustine Osasemeaga Okpiabhele
Department of Biochemistry, Faculty of Natural and Applied Sciences, Michael and Cecilia Ibru University, Ughelli, Delta State, Nigeria; Tel.: (+234-8101)339498; Email: okpiabheleaustin405@gmail.com; ORCID ID: 0000-0002-2552-2732

1. INTRODUCTION

Pancreatic toxicity is the injury and dysfunction of the pancreas caused by external factors such as certain drugs, chemicals, or toxins, which lead to acute or chronic pancreatitis. The damage typically arises from the reaction of the body to a toxin or the interaction of the toxin and its metabolites with pancreatic tissue, resulting in inflammation, necrosis, and long-term organ damage[1]. To detect early-stage pancreatic injury and develop effective therapeutic measures, one should understand the mechanisms behind pancreatic injury and identify specific and sensitive biomarkers[2]. Figure

[Downloaded from ibj1.pasteur.ac.ir on 2026-10-16]

[DOI: 10.22034/IBJ.30.3.132]

S1 shows the molecular mechanism of *Vernonia amygdalina* ethanol extract on the pancreas of rats exposed to 1,2-dimethylhydrazine (DMH) toxicity.

DMH is a potent colon toxicant that induces colorectal tumors in experimental animals and serves as a widely used model for chemically induced colon toxicity, potentially leading to carcinogenesis[3].

Numerous studies have investigated the toxic effects of DMH on various organs, including the colon[4], liver[5], kidney[6], and brain[7]; however, there is limited information regarding its effect on the pancreas. DMH closely resembles human colorectal toxicity, particularly in response to certain promotional and preventive agents[8]. The models used in DMH toxicity studies have been developed to explore the pharmacological properties of plant-derived components, as they often exhibit similar mechanisms of action and pathological changes comparable to those observed in humans[9].

Medicinal plants have long served as valuable sources for drug development in both developing and developed countries. There is a growing interest in complementary and alternative medicines for treating various acute and chronic diseases[10]. Most biologically active compounds isolated from natural plant products have been recognized as either nontoxic or less toxic to normal cells, gaining attention from scientists and clinicians in the present drug discovery era[11].

Vernonia amygdalina, also known as bitter leaf, is a medicinal plant widely used in traditional medicine across various parts of Nigeria. The leaves of this plant contain numerous bioactive compounds that offer a range of potential health benefits[12]. While *V. amygdalina* is rich in biologically active compounds that help reduce oxidative stress caused by accumulated free radicals[13], there is no evidence supporting its remedial effects on systemic toxicity induced by DMH in organs such as the pancreas. Hence, this study was conducted to investigate the therapeutic potential of *V. amygdalina* in suppressing DMH-induced pancreatic toxicity in Wistar rats.

2. MATERIALS AND METHODS

2.1. Chemicals and reagents

The chemicals, reagents, and solvents used in this study were of analytical grade. They were purchased from Sigma-Aldrich Ltd. (St. Louis, MO, USA), Randox Ltd. (UK), and Pyrex Ltd. (Nigeria).

2.2. Preparation of *V. amygdalina* extract

Fresh mature leaves of the plant (Fig. S2A) were obtained from a vegetable farm in Benin City, Edo State, Nigeria. The leaves were identified and authenticated at the Herbarium of the Department of Plant Biology and Biotechnology at the University of Benin, where they were assigned the voucher number UBH-V342. The leaves were separated from the stalk, washed (Fig. S2B), and air-dried at room temperature (24°C). Once dried, they were pulverized, crushed into a fine powder, and weighed. The ethanol extract of *V. amygdalina* leaves was prepared by soaking 400 g of the powdered plant leaves in 1,000 ml of absolute ethanol at room temperature for 72 h. The extract was thereafter filtered first through Whatman filter paper no. 42 (125 mm) and then through cotton wool. The extract was concentrated using a rotary evaporator at 40ºC to one-tenth of its original volume, and further processed with a freeze-drier. The resulting dried residue was stored at 4ºC. Portions of the crude plant extract were weighed, dissolved in distilled water, and kept for experimental analysis.

2.3. Experimental animal design of the study

Male Wistar albino rats, weighing 150–200 g, were obtained from the Animal House of the Department of Biochemistry at the University of Benin. They were accommodated in clean, disinfected cages under standard laboratory conditions, with access to feed (pelletized growers' mash) and water ad libitum. The rats were acclimatized for two weeks before initiation of the experiment. Rats were randomly assigned to eight groups (five rats per group) as shown in Table 1. The groups included control, DMH (40 mg/kg body weight), silymarin (100 mg/kg body weight), *V. amygdalina* (300 mg/kg body weight), pretreatment (200 mg/kg body weight), pretreatment (400 mg/kg body weight), post-treatment (200 mg/kg body weight), and post-treatment (400 mg/kg body weight) groups. Except for the control and *V. amygdalina* groups, all rats were exposed to DMH before or after treatment with *V. amygdalina* via the intraperitoneal route, administered as a single dose of 40 mg/kg body weight[14]. Rats in the silymarin group were treated with the standard hepato-/cardio-protective drug, silymarin (100 mg/kg body weight). The body weight of rats in all groups was recorded at weekly intervals for 21 days, and the treatment duration was the same throughout this time frame.

2.4. Tissue sample collection and preparation

At the end of the experiment, pancreatic tissues were excised and blotted dry to obtain their wet weight using an electronic weighing balance. Thereafter, the tissues were homogenized and used for biochemical analysis, which included the following tests: amylase, total protein, nitric oxide (NO), superoxide dismutase (SOD), catalase (CAT), malondialdehyde (MDA), glutathione (GSH), glutathione peroxidase (GPx), GR, and concentration of reduced GSH.

[Downloaded from ibj1.pasteur.ac.ir on 2026-10-16]

[DOI: 10.22034/IBJ.30.3.132]

Table 1. Experimental design

Groups	Treatments
G1	Control
G2	DMH only (40 mg/kg body weight)
G3	Silymarin (100 mg/kg body weight)
G4	*V. amygdalina* leaf extract only (300 mg/kg body weight)
G5	Pretreatment–*V. amygdalina* leaf extract (200 mg/kg body weight) for 18 days, followed by DMH (40 mg/kg body weight)
G6	Pretreatment–*V. amygdalina* leaf extract (400 mg/kg body weight) for 18 days, followed by DMH (40 mg/kg body weight)
G7	Post-treatment – DMH (40 mg/kg body weight) on day 0, then followed by *V. amygdalina* leaf extract (200 mg/kg body weight) for three weeks
G8	Post-treatment – DMH (40 mg/kg body weight) on day 0, then followed by *V. amygdalina* leaf extract (400 mg/kg body weight) for three weeks

2.5. Biochemical analysis

The pancreatic tissues were homogenized in ice-cold phosphate buffer using a mechanical grinder. The tissue homogenates were then centrifuged in a refrigerated centrifuge at 3,500 ×g at 4°C for 10 min. The resulting supernatants were aliquoted and stored at -20°C for later determination of pancreatic parameters related to oxidative stress and lipid peroxidation.

2.6. Measurement of total protein concentration

The most widely used method for measuring serum protein is the biuret reaction, as described before[15]. In this reaction, serum proteins react with copper sulfate in sodium hydroxide to form a violet biuret complex. The intensity of the violet color was measured using a spectrophotometer, which was proportional to the concentration of protein.

2.7. Measurement of NO concentration

To assess nitrosative stress, we measured the NO content in the pancreatic tissue homogenates using the Griess reaction. In this process, NO was transformed to nitrite, a more stable metabolite, which is then converted to HNO_2 in an acidic environment. Subsequently, HNO_2 reacted with sulfanilamide to form a diazonium salt, which then reacted with N-(1-naphthyl) ethylenediamine to generate an azo dye, detectable at 540 nm. The NO content of the examined pancreatic tissue specimens was expressed as nmol per mg of protein, with a concentration range of 1.56 µM and an R^2 value of 0.995[16].

2.8. Measurement of lipid peroxidation index

MDA was estimated in pancreatic tissue homogenate supernatants using the thiobarbituric acid reacting substance (TBARS) assay, as described previously[17]. First, 100 µL of the supernatant was diluted 20 times in 0.15 M Tris-KCl buffer and then deproteinized by adding 500 µL of trichloroacetic acid (30%). The mixture was centrifuged in a bench-top centrifuge at 4,000 ×g at room temperature for 10 min. Following centrifugation, 200 µL of the supernatant was transferred to an Eppendorf tube, followed by the addition of 200 µL of thiobarbituric acid (0.75%). The mixture was then heated at 80°C for 1 h. After cooling the tubes on ice, 200 µL of the mixture was transferred to a microtiter plate, and absorbance was measured at 532 nm. The concentration of TBARS in the tissues was expressed as nmol MDA/mg protein.

2.9. Measurement of oxidative stress parameters

Superoxide dismutase enzyme activity was determined in pancreatic tissues using the autooxidation of adrenaline assay method as described formerly[18]. CAT enzyme activity in pancreatic tissue supernatants was determined using the colorimetric assay based on the formation of a yellow complex with H_2O_2 and molybdate[19]. GSH content in tissue samples was determined as previously described[20]. Briefly, pancreatic tissue homogenate (1.0 mL) was mixed with 0.1 mL of 25% trichloroacetic acid. The mixture was then centrifuged at 5,000 ×g for 10 min to remove the precipitate. The supernatant (0.1 mL) was mixed with 2 mL of 0.6 mM 5,5'-dithio-bis(2-nitrobenzoic acid), prepared in 0.2 M sodium phosphate buffer at pH 8.0. Absorbance was read at 412 nm. GPx activity was determined by monitoring the oxidation of NADPH to $NADP^+$ in the presence of H_2O_2 as a substrate, using a spectrophotometer at 340 nm for 3 minutes. GPx activity was expressed as micromoles of NADPH/min/g of protein using an extinction coefficient of 6.22 mM^{-1} cm^{-1} for NADPH.

2.10. Histopathological examination of pancreatic tissues

Pancreatic tissue specimens, fixed in 10% phosphosaline, were examined microscopically for structural alterations at the University of Benin Teaching Hospital. The slides were processed and stained with hematoxylin and eosin. Photomicrographs of the stained slides were captured using an Olympus microscope (Olympus, New Jersey, USA) connected to a computer through a digital camera.

[Downloaded from ibj1.pasteur.ac.ir on 2026-10-16]

[DOI: 10.22034/IBJ.30.3.132]

2.11. Statistical analysis

All statistical analyses were performed using the SPSS software tool (version 20, IBM Corporation, New York, USA). Data obtained from this study were expressed as mean ± standard error of the mean (SEM). Statistical evaluation was performed using the one-way analysis of variance (ANOVA). A post-hoc comparison test was carried out using Tukey's HSD to evaluate pairwise differences among group means. Differences between groups were considered significant at $p < 0.05$.

3. RESULTS

3.1. Effect of ethanol extract of *V. amygdalina* leaves on the body weight of rats

The results obtained for the body weight of rats, as shown in Figure 1, indicated that the DMH group exhibited a significant reduction ($p < 0.05$) in the final body weight when compared to the control. In contrast, the treatment groups showed a significant increase ($p < 0.05$) in body weight when compared to the DMH group. Notably, the silymarin group demonstrated a significant increase ($p < 0.05$) in the final body weight compared to the other groups.

3.2. Effect of ethanol extract of *V. amygdalina* leaves on body weight change in rats

As shown in Figure 2, there was a percentage decrease ($p < 0.05$) in body weight change of rats in the DMH group when compared with the control. Furthermore, groups treated with ethanol extract of *V. amygdalina* leaves, before and after DMH administration, showed a percentage increase ($p < 0.05$) in the body weight change relative to the DMH group.

3.3. Effect of ethanol extract of *V. amygdalina* leaves on the weight of pancreatic tissues

There was a significant increase ($p < 0.05$) in the relative weight of the pancreatic tissues in the DMH group relative to the control, as shown in Figure 3. Additionally, there were significant differences ($p < 0.05$) among the various groups that received *V. amygdalina* extract before and after DMH induction, particularly when compared to silymarin and *V. amygdalina* groups, respectively.

3.4. Effect of ethanol extract of *V. amygdalina* on antioxidant enzymes in pancreatic tissues

Intraperitoneal injection of a single dose of DMH (40 mg/kg body weight) in Wistar albino rats resulted in significant reductions ($p < 0.05$) in the level of pancreatic antioxidant enzymes (catalase, SOD, GPx, GSH, GR, and reduced GSH percentage) when compared to the control (Fig. 4). However, treatment of rats with ethanol extract of *V. amygdalina* leaves significantly increased ($p < 0.05$) the levels of the antioxidant enzymes relative to DMH group.

3.5. Effect of ethanol extract of *V. amygdalina* on total protein levels, amylase activity, NO, and MDA in pancreatic tissues

There was a significant increase ($p < 0.05$) in the mean values of pancreatic α-amylase, NO, total protein, and MDA levels in the DMH group when compared to the control (Fig. 5). Conversely, treatment of rats with

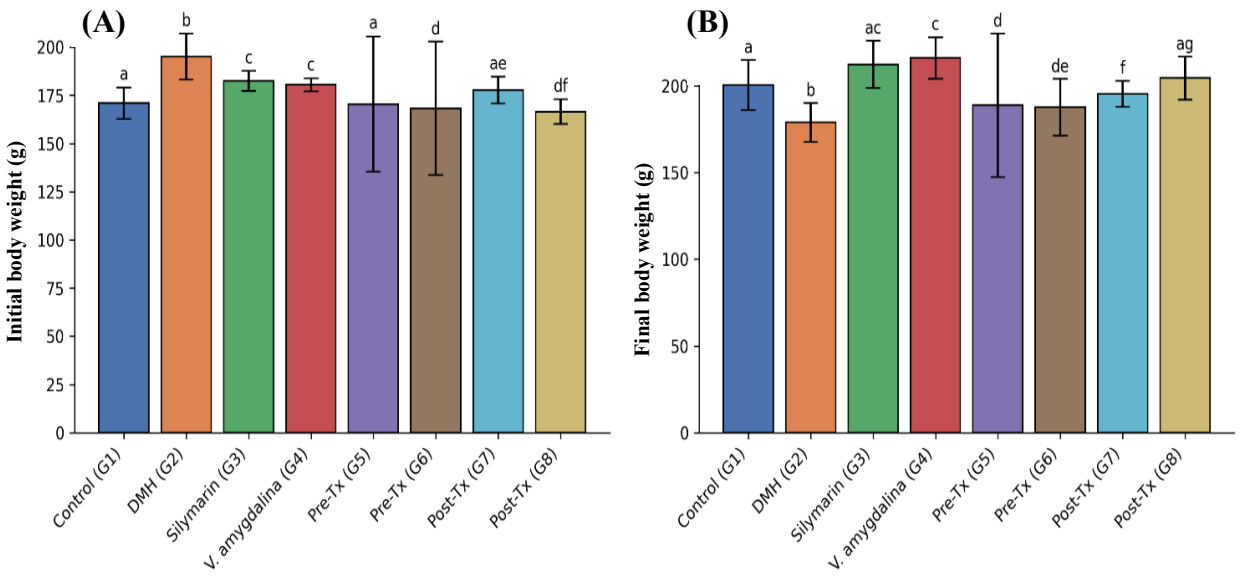

Fig 1. Body weight of rats: initial (A) and final (B) body weight. For all parameters, values having different superscripts among groups are significantly different ($p < 0.05$). Values are stated as mean ± SEM (n = 5).

[Downloaded from ibj1.pasteur.ac.ir on 2026-10-16]

[DOI: 10.22034/IBJ.30.3.132]

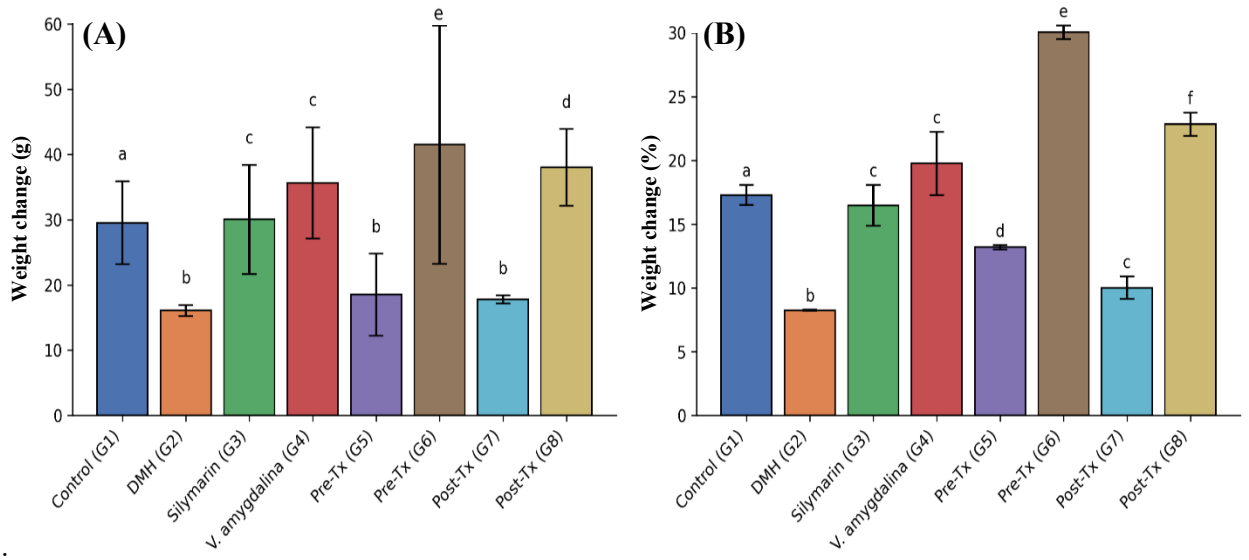

Fig. 2. Body weight change in rats: (A) weight change and (B) percentage of weight change. For all parameters, values having different superscripts among groups are significantly different ($p < 0.05$). Values are stated as mean ± SEM (n = 5).

ethanol extract of *V. amygdalina* leaves significantly decreased ($p < 0.05$) the levels of pancreatic α-amylase, NO, total protein, and MDA relative to the DMH group.

4. DISCUSSION

In this study, we investigated the therapeutic potential of *V. amygdalina* in mitigating pancreatic toxicity induced by DMH in rats. The results showed that the administration of DMH caused significant oxidative stress and histopathological damage in the pancreas, characterized by increased levels of pancreatic function parameters, reduced concentrations of antioxidant markers, and severe histological alterations.

As previously mentioned, exposure to DMH can lead to weight loss, which is often used as an indicator of toxicity and is frequently studied in research investigating potential preventive treatments for various diseases[21]. In this study, we observed a significant reduction ($p < 0.05$) in the body weight of rats in the DMH group. This reduction is typical when the body is exposed to toxicants. Moreover, the significant changes were seen in the body and pancreatic tissue weight of the rats treated with the ethanol extract of *V. amygdalina* leaves, relative to the DMH group, confirming that the extract has beneficial properties for weight management. This finding aligns with earlier

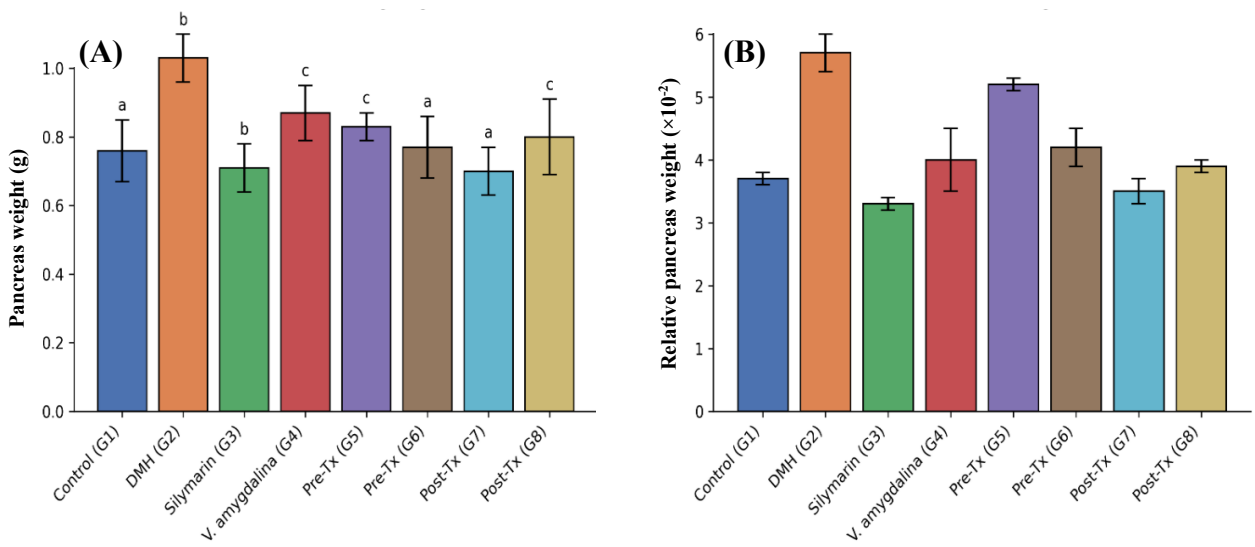

Fig. 3. Relative weight of pancreas in rats: (A) pancreas weight and (B) relative pancreas weight. For all parameters, values having different superscripts among groups are significantly different ($p < 0.05$). Values are stated as mean ± SEM (n = 5).

[Downloaded from ibj1.pasteur.ac.ir on 2026-10-16]

[DOI: 10.22034/IBJ.30.3.132]

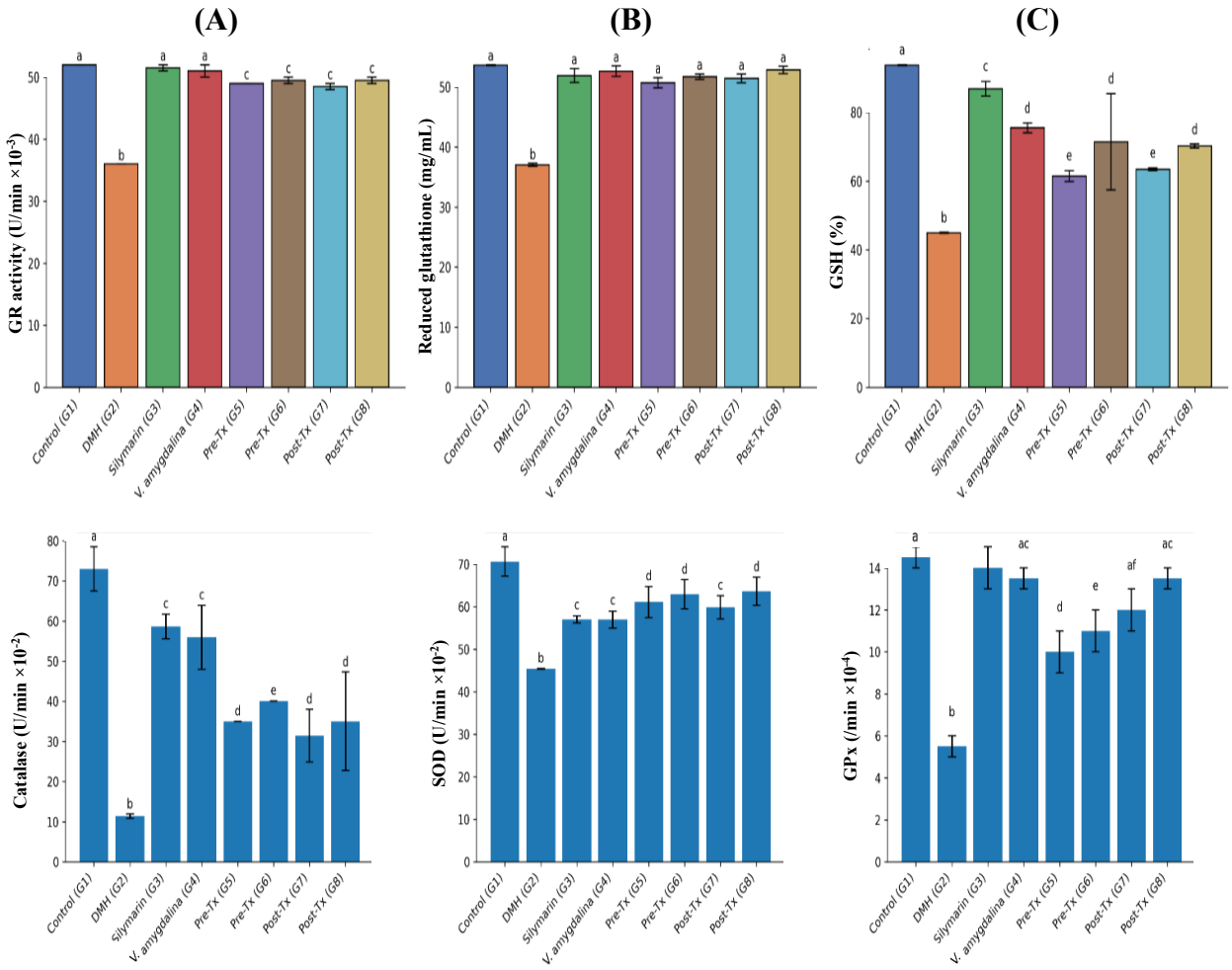

Fig. 4. Activities of antioxidant enzymes in pancreatic tissues: (A) catalase and GR activity, (B) SOD and reduced glutathione, and (C) GPx and percentage of GSH. For all parameters, values having different superscripts among groups are significantly different ($p < 0.05$). Values are stated as mean ± SEM (n = 5).

studies that suggested that the saponin extract of *V. amygdalina* exhibits similar effects[22].

Antioxidant enzymes play a crucial role in protecting against damage caused by free radicals and reactive oxygen species resulting from DMH-induced systemic toxicity. These enzymes, including SOD, CAT, and GPx, help neutralize harmful molecules and maintain cellular health[23]. Notably, pancreatic islets, which produce insulin, are known to express lower levels of antioxidant enzyme genes compared to other tissues, making them more vulnerable to damage[24]. In our study, the intraperitoneal injection of a single dose of DMH (40 mg/kg body weight) in Wistar albino rats caused significant reductions ($p < 0.05$) in the content of pancreatic antioxidant enzymes (CAT, SOD, GPx, GSH, GR, and reduced GSH percentage) compared to the control and other groups. Although there was no direct link between DMH toxicity and pancreatic effects, the observed changes in antioxidant parameters suggest that DMH can induce oxidative stress, which plays a significant role in pancreatic diseases, particularly pancreatitis and beta-cell dysfunction. However, treatment of rats with ethanol extract of *V. amygdalina* leaves significantly increased ($p < 0.05$) the levels of the antioxidant enzymes relative to the DMH group. This observation aligns with other reports claiming that *V. amygdalina* contains bioactive compounds, responsible for its biological effects and enhanced activities of the antioxidant enzymes[25,26].

Earlier reports based on in vivo studies in animals have indicated that amylase and proteolytic enzymes in pancreatic tissues are rapidly depleted at the initiation of severe pancreatitis[27]. Additionally, excessive production or imbalances of NO can contribute to pancreatic damage and inflammation[28]. Our study showed a significant increase ($p < 0.05$) in the mean values of pancreatic α-amylase, NO, total protein, and MDA in the DMH group when compared to the control.

[Downloaded from ibj1.pasteur.ac.ir on 2026-10-16]

[DOI: 10.22034/IBJ.30.3.132]

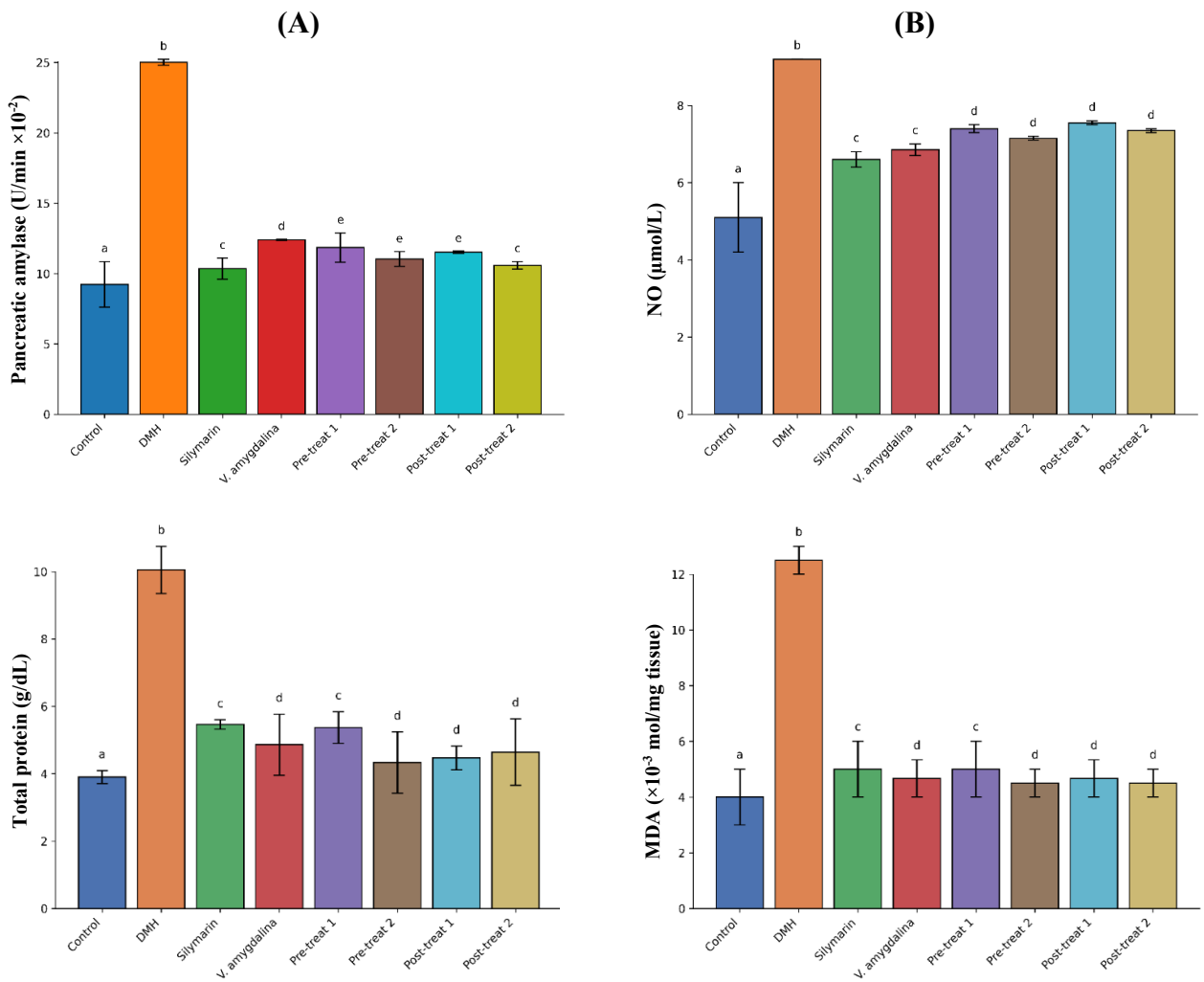

Fig. 5. Amylase activity and levels of NO, total protein, and malondialdehyde in pancreatic tissues: (A) pancreatic amylase and total protein, (B) NO and MDA. For all parameters, values having different superscripts among groups are significantly different ($p < 0.05$). Values are stated as mean ± SEM (n = 5).

Although research that directly addresses the effects of DMH on pancreatic amylase and MDA is limited, our findings suggest that the remarkable elevations of these parameters may result from increased lipid peroxidation, glucose abnormalities, oxidative stress, inflammation, and changes in protein synthesis. Consequently, treatment with the ethanol extract of *V. amygdalina* leaves significantly decreased ($p < 0.05$) the levels of pancreatic α-amylase, NO, total protein, and MDA relative to the DMH group. This observation suggests that the extract is effective against pancreatic abnormalities and oxidative stress due to its bioactive compounds, such as saponins and flavonoids, which ensure that the pancreas maintains its endocrine and exocrine functions[29-32].

In the histopathological studies (Fig. S3-S10), the morphological abnormalities observed in the DMH group included islet shrinkage, necrotic areas, cellular degeneration, and disorientation of islet cells, which align with an earlier report[33]. Furthermore, the treatment with *V. amygdalina*, administered before or after DMH induction at lower and higher doses, suggests that the extract activates the recovery of pancreatic function by regenerating destroyed beta cells, as similarly observed in previous research[34].

5. CONCLUSION

Our findings indicate that *V. amygdalina* ethanol extract can alleviate oxidative stress related to DMH-induced pancreatic toxicity, thereby promoting pancreatic health.

DECLARATIONS

Acknowledgements

Not applicable.

[Downloaded from ibj1.pasteur.ac.ir on 2026-10-16]

[DOI: 10.22034/IBJ.30.3.132]

Generative AI and AI-assisted technologies

During the preparation of this manuscript, the authors used Grammarly to check spelling errors and Turnitin to check for plagiarism. After using this tool/service, the authors reviewed and edited the content and take full responsibility for the content of the published article.

Ethics approval

All the experimental procedures in this study were conducted in accordance with the Institutional Animal Care guidelines of the National Institute of Health in the "Principles of Laboratory Animal Care" (NIH Publication No. 85 − 23) and approved by the Research Ethics Committee of the University of Benin, Benin City, Edo State, Nigeria (ethical code: FLS/REC/2025/005).

Consent to Participate

Not applicable.

Consent for publication

All authors reviewed the results and approved the final version of the manuscript.

Authors' contributions

AOO: conceived the idea for the work, designed the methodology/experiment plan for the study, was involved in carrying out the analysis and interpretation of data generated in this study, provided resources such as assay kits and laboratory equipment for this study, prepared the original draft/manuscript of this work; ODA: designed the methodology/experiment plan for the study, was involved in carrying out the analysis and interpretation of data generated in this study, provided resources such as assay kits and laboratory equipment for this study, substantively reviewed and edited the work, approved the submitted version of the work; AEA: provided resources such as assay kits and laboratory equipment for this study, substantively reviewed and edited the work, approved the submitted version of the work.

Data availability

All relevant data can be found within the manuscript.

Competing interests

The authors declare that they have no competing interests.

Funding

This research received no specific grant from any funding agency in the public, commercial, or not-for-profit sectors.

Supplementary information

The online version contains supplementary material.

REFERENCES

1. Matthew W, John MS. Exocrine Pancreas. In book: Fundamentals of toxicologic pathology. 3rd ed. Academic Press. 2018:443-58.
2. Kaphalia BS. Pancreatic toxicology: Encyclopedia of environmental health. Elsevier. 2011:315-24.
3. Newell LE, Heddle JA. The potent colon carcinogen, 1,2-dimethylhydrazine induces mutations primarily in the colon. Mutat Res. 2004;564(1):1-7.
4. Caetano BFR, Tablas MB, Romualdo GR, Rodrigues MAM, Barbisan LF. Early molecular events associated with liver and colon sub-acute responses to 1,2-dimethylhydrazine: Potential implications on preneoplastic and neoplastic lesion development. Toxicol Lett. 2020:329:67-79.
5. Ezz W, Moawed F, Abo Zaid O. The potential ameliorating effect of 5-fluorouraciL nanoparticles on 1,2-Dimethylhydrazine-induced hepatotoxicity in rats. Benha Vet Med J. 2024;46(1):54-7.
6. Sunter JP, Senior PV. Induction of renal tumours in rats by the administration of 1,2 dimethylhydrazine. J Pathol. 1983; 140(1):69-76.
7. Pandey S, Singh A, Chaudhari N, Nampoothiri LP, Kumar GN. Protection against 1,2-di-methylhydrazine-induced systemic oxidative stress and altered brain neurotransmitter status by probiotic Escherichia coli CFR 16 secreting pyrroloquinoline quinone. Curr Microbiol. 2015;70(5):690-7.
8. Saini MK, Sharma P, Kaur J, Sanyal SN. The cyclooxygenase-2 inhibitor etoricoxib is a potent chemopreventive agent of colon carcinogenesis in the rat model. J Environ Pathol Toxicol Oncol. 2009;28(1):39-46.
9. Corpet DE, Pierre F. How good are rodent models of carcinogenesis in predicting efficacy in humans? A systematic review and meta-analysis of colon chemoprevention in rats, mice and men. Eur J Cancer. 2005;41(13):1911-22.
10. Chaachouay N, Zidane L. Plant-derived natural products: A source for drug discovery and development. Drugs Drug Candidates. 2024;3(1):184-207.
11. Najmi A, Javed SA, Al-Bratty M, Alhazmi HA. Modern approaches in the discovery and development of plant-based natural products and their analogues as potential therapeutic agents. Molecules. 2022;27(2):349.
12. Farombi EO, Owoeye O. Antioxidative and chemopreventive properties of Vernonia amygdalina and garcinia biflavonoid. Int J Environ Res Public Health. 2011;8:(6):2533-55.
13. Edo GI, Jikah AN, Onoharigho FO, Akpoghelie PO, Agbo JJ, Ekokotu HA, et al. The ameliorative effects of Vernonia amygdalina extract on superoxide dismutase and glutathione s-transferase on alloxan-induced diabetes on male Wistar rats, Food Chemist Adv. 2024;4:100620.
14. Venkatachalam K, Vinayagam R, Anand MAV, Mat Isa N, Ponnaiyan R. Biochemical and molecular aspects of 1,2-dimethylhydrazine (DMH)-induced colon carcinogenesis: A review. Toxicol Res. 2020;9(1):2-18.
15. Sari NPYP, Amril A, Muttaminnah M. Total protein

[Downloaded from ibj1.pasteur.ac.ir on 2026-10-16]

[DOI: 10.22034/IBJ.30.3.132]

examination using the biuret method. Int J Sci Adv. 2024;5(6):1081-5.
16. Moorcroft M, Davis J, Compton RG. Detection and determination of nitrate and nitrite: A review. Talanta. 2001;54(5):785-803.
17. Rizzo M. Measurement of malondialdehyde as a biomarker of lipid oxidation in fish. Am J Analyt Chem. 2024;15(9):303-32.
18. Misra HP, Fridovich I. The role of superoxide anion in the autooxidation of epinephrine and- a simple assay for superoxide dismutase. J Biol Chem. 1972;247(10):3170-5.
19. Góth L. A simple method for determination of serum catalase activity and revision of reference range. Clin Chim Acta. 1991;196(2-3):143-51.
20. Ellman GL. Tissue sulfhydryl groups. Arch Biochem Biophys. 1959;82(1):70-7.
21. Umeaku U, Ofusori DA, Umeaku OP, Edward TA. The effect of aqueous extract of ocimum gratissium (Linn) on 1, 2 - dimethyl hydrazine induced colon cancer in male Wistar rats. Int J Hum Anat. 2020; 2:(1):22-35.
22. Obike C, Ijeh II, Egbuonu ACC, Ubah EE. Body and organ weight changes in male Wistar rats treated with saponin extract of Vernonia amygdalina and Vernonia colorata. Sci Afr. 2024;23(3):133-46.
23. Pence CB. Dietary selenium and antioxidant status: Toxic effects of 1,2-dimethylhydrazine in rats1. J Nutr. 1991;121(1):138-44.
24. Ertik O, Bayrak BB, Sener G, Yanardag R. Melatonin improves liver and pancreatic tissue injuries in diabetic rats: Role of antioxidant enzymes. J Diabetes Metab Disord. 2023;22(1):591-602.
25. Ozor CC, Anioba FO, Ozoemena CL. Protective effect of methanolic extract of Vernonia amygdalina (Bitter-Leaf) on alloxan-induced pancreatic toxicity in adult Wistar rats. Asian J. Res. Rep. Endocrinol. 2023;6(1):68-76.
26. Djeujo FM, Stablum V, Pangrazzi E, Ragazzi E, Froldi G. Luteolin and vernodalol as bioactive compounds of leaf and root Vernonia amygdalina extracts: Effects on α-glucosidase, glycation, ROS, cell viability, and in silico ADMET parameters. Pharmaceutics. 2023;15(5):1541.
27. Turner MD, Correll WW, Fain WR, Conn JH, Cockrell JV. Enzyme levels in pancreatic tissue and body fluids during experimental pancreatitis, J Surg Res. 1963;3(10):485-90.
28. Yago MD, Mañas M, Ember Z, Singh J. Nitric oxide and the pancreas: Morphological base and role in the control of the exocrine pancreatic secretion. Mol Cell Biochem. 2001;219(1-2):107-20.
29. Hamiza OO, Rehman MU, Tahir M, Khan R, Khan AQ, Lateef A, et al. Amelioration of 1,2 dimethylhydrazine (DMH) induced colon oxidative stress, inflammation and tumor promotion response by tannic acid in Wistar rats. Asian Pac J Cancer Prev. 2012;13(9):4393-402.
30. Thi CT, Nguyen C-Q, Vi PV, Dang QL, Tuấn ND, Huynh P, et al. Morphology of Vernonia amygdalina L. and study of its antioxidant property, α-amylase and α-glucosidase inhibitory activity, hepatoprotective potency and toxicity. Trop J Nat Prod Res. 2024;8(5):7128-33.
31. Adedapo AA, Aremu OJ, Oyagbemi AA. Anti-oxidant, anti-inflammatory and antinociceptive properties of the acetone leaf extract of Vernonia amygdalina in some laboratory animals. Adv Pharm Bull. 2014;4(2):591-8.
32. Ilechukwu C, Ezenwelu CO, Ifemeje JC, Ikechukwu JN, Iheukwumere IH. Comparative assessment of the in vitro antioxidant activity and phytochemical analysis of Vernonia amygdalina leaf and Ocimum gratissimum leaf. J Drug Dis Res Rev. 2025;3(2):38-43.
33. Elkort RJ, Handler AH, Mozden PJ. Preneoplastic changes in rabbit pancreatic duct cells produced by dimethylhydrazine. Int J Cancer. 1975;16(5):810-8.
34. Atangwho IJ, Edet EE, Uti DE, Obi AU, Asmawi MZ, Ahmad M. Biochemical and histological impact of Vernonia amygdalina supplemented diet in obese rats. Saudi J Biol Sci. 2012;19(3):385-92.

[Downloaded from ibj1.pasteur.ac.ir on 2026-10-16]

[DOI: 10.22034/IBJ.30.3.132]