SHORT COMMUNICATION	Iranian Biomedical Journal 29 (3): 167-172 May 2025

Migration Pattern and Tissue Tropism of *Toxascaris leonina* (Linstow, 1902) Larvae: An *in vivo* Evaluation

Mohammad Sardari[1], Alireza Nourian[2], Farzad Parsa[3], Salman Zafari[4], Heshmatollah Taherkhani[5], Amir Hossein Maghsood[1], Mohammad Matini[1], Seyed Mousa Motevali Haghi[1], Mohammad Fallah[1*]

[1]Department of Medical Parasitology and Mycology, School of Medicine, Hamadan University of Medical Sciences, Hamadan, Iran; [2] Department of Pathobiology, Faculty of Veterinary Science, Bu-Ali Sina University, Hamedan, Iran; [3]Department of Medical Laboratory Sciences, Borujerd Branch, Islamic Azad University, Borujerd, Iran; [4] Department of Medical Parasitology and Mycology, School of Public Health, Tehran University of Medical Science, Tehran, Iran; [5]Department of Medical Laboratory Sciences, Faculty of Paramedical Sciences, Islamic Azad University, Tehran, Iran

OPEN ACCESS

Article type: Research Article
Received: March 22, 2025
Revised: April 25, 2025
Accepted: May 24, 2025
Published online: May 25, 2025

How to cite:
Sardari M, Nourian A, Parsa F, Zafari S, Taherkhani H, Maghsood AH, Matini M, Motevali Haghi SM, Fallah M. Migration Pattern and Tissue Tropism of *Toxascaris leonina* (Linstow, 1902) Larvae: An *in vivo* Evaluation. *Iran. Biomed. J.* 2025; 29(3): 167-172.

This article is licensed under a Creative Commons Attribution-NonDerivatives 4.0 International License.

ABSTRACT

Background: The role of *T. leonina* in visceral larva migrans is controversial. This study aimed to investigate the migratory behavior of *T. leonina* larvae across different organs in mice.
Methods: Six-week-old Swiss albino mice (n = 26) were randomly allocated into six experimental groups and one control group. Each mouse in the experimental groups was orally inoculated with 1,000 embryonated *T. leonina* eggs. The animals were euthanized at 2, 5, 10, 15, 20 and 30 dpi. Tissue samples were examined for larval presence and associated pathological changes using digestive and histopathological methods. The squash method was used for brain tissue analysis.
Results: *T. leonina* larvae were recovered from the small intestinal wall, lungs, liver, and striated muscles. No larvae were detected in the kidneys, heart, spleen, and brain using digestive or squash methods. Histological examination revealed granulomatous reactions, inflammatory cell accumulation, and larval presence in the isolated tissues. Larval concentration in the striated muscles increased over time, demonstrating the potential of Swiss albino mice to serve as paratenic hosts in toxocariasis.
Conclusion: Our study exhibits that Swiss albino mice are susceptible to *T. leonina* infection, with larvae localizing primarily in the small intestinal wall, liver, lungs, and striated muscles. ***DOI: 10.61882/ibj.4998***

Keywords: Larva migrans, Toxocariasis, Tropism

Corresponding Author: Mohammad Fallah
Department of Medical Parasitology and Mycology, School of Medicine, Hamadan University of Medical Sciences, Hamadan, Iran; Tel.: (+98-918) 1113650; Fax: (+98-81) 38218991; E-mail: fallah@umsha.ac.ir; ORCID ID: 0000-0003-1759-7387

INTRODUCTION

Toxascaris leonina, an intestinal nematode of canids and felids, is generally considered less pathogenic than *Toxocara* species in dogs and cats[1-3]. The parasite's eggs are shed in the feces of definitive hosts— primarily canines (e.g. dogs and wolves) and felines (e.g. cats). These eggs are ingested by the intermediate hosts, typically rodents, and transmission to definitive hosts occurs through ingesting the infected rodents or directly via embryonated eggs[4-6]. Notably, cats appear to be more susceptible to infection than dogs[5].

Unlike *Toxocara* species, *T. leonina* does not undergo trans-mammary or transplacental transmission[7]. Genomic studies have demonstrated distinct genetic variations between *T. leonina* strains isolated from dogs and South Chinese tigers[8]. Prevalence rates are

List of Abbreviations:
dpi: days post-infection; **H&E:** Hematoxylin and eosin; ***T. leonina***: *Toxascaris leonina*

[Downloaded from ibj1.pasteur.ac.ir on 2026-10-16]
[DOI: 10.61882/ibj.4998]

significantly higher in stray animals (6.6% in dogs and 8.0% in cats) than that in owned pets, particularly in low-income regions[6,9,10].

Clinical signs of infection are often mild and limited to gastrointestinal disturbances, although rare cases of intestinal obstruction have been reported[11]. The zoonotic potential of *T. leonina* remains under investigation. However, its possible involvement in human eosinophilia has been suggested in areas such as St. Larsen Island, where larvae have been found in paratenic hosts (arctic foxes and rodents)[12]. While *Toxocara* larvae are known to migrate to the brain, *T. leonina* larvae invade the intestine, liver, lungs, and striated muscles, though their exact migratory pathways is unclear.

In rodent models, larval development occurs over a period of 2-3 months, with larvae reaching 877 µm in length by 60 dpi[13]. Although various experimental studies have reported larval development in rodents, the spatiotemporal distribution and tissue tropism of *T. leonina* larvae in paratenic hosts have not been sufficiently understood. The present study aimed to examine the migratory patterns of *T. leonina* larvae in Swiss albino mice to elucidate its pathogenic mechanisms and contribute to the improvement of clinical management strategies.

MATERIALS AND METHODS

Egg collection and preparation

T. leonina eggs were collected from adult female worms isolated from naturally infected dogs in Boroujerd County, Lorestan Province, Iran. Egg isolation was carried out using two methods: (1) incubation of gravid worms in 0.15 M of NaCl at 37 °C for 24 hours to induce egg deposition[14] and (2) saline washing and grinding worms to release uterine eggs. The collected eggs were sieved, washed, and kept in 1% formalin-saline at room temperature for one week to allow larval embryonation[15]. The embryonated eggs were subsequently stored at 2-8 °C until use.

Experimental design

Twenty-six male Swiss albino mice (six weeks old, 20-30 g) were obtained from Shahid Beheshti University, Tehran, Iran. The animals were acclimatized for one week at the laboratory of Hamadan University of Medical Sciences (Hamadan, Iran) under controlled conditions (20–22 °C, 60 ± 10% humidity, 12-hour light/dark cycle). Mice were divided into one control group (n = 2) and six experimental groups (n = 4 per group). Embryonated *T. leonina* eggs were washed with phosphate-buffered saline to remove formalin. Egg viability was confirmed by observing larval movement under an inverted microscope. The egg concentration (1,000-1,050 eggs/mL) was determined using light microscopy. Mice were fasted overnight, orally inoculated with 0.5 mL of the egg suspension via gastric tube, and housed without bedding for 48 hours. Fecal samples were examined using the Sheather's method[16].

Tissue digestion and larval recovery

Mice were euthanized at 2, 5, 10, 15, 20, and 30 dpi using intraperitoneal injection of ketamine-xylazine (50 mg/kg ketamine and 5 mg/kg xylazine). Larvae were isolated from the small intestine, spleen, liver, lungs, heart, kidneys, and striated muscles using pepsin digestion. In this method, tissues were minced and incubated in a digestion solution containing pepsin and hydrochloric acid at 37-45 °C, allowing tissue breakdown while preserving larvae. The resulting sediment was fixed in iodine solution, decolorized with sodium thiosulfate, and examined under a dissecting microscope for larval counting[17]. Brain tissue samples were analyzed using the squash method, in which samples were compressed between two microscope slides and examined under a light microscope (Olympus, Japan)[18].

Histopathologic analysis

Tissue samples from the lungs, liver, muscles, intestine, heart, kidneys, and spleen were fixed in 10% neutral buffered formalin, and then dehydrated, embedded in paraffin, and sectioned at 5 µm thickness. The sections were stained with H&E and examined under a light microscope[19]. For each organ, 10 to 20 sections were analyzed at magnifications of ×40 and ×400.

Statistical analysis

Statistical data analysis was performed using SPSS software (version 16.0, Chicago, IL, USA). The nonparametric Kruskal-Wallis test was used to assess differences in larval recovery data across tissues at various time points. Data were considered statistically significant at $p < 0.05$.

RESULTS

Experimental infection was successful in all mice except those in the control group, as *T. leonina* larvae were detected in all autopsied experimental animals. No larvae were found in the kidneys, heart, spleen, and brain tissues of the experimental mice throughout the study period. The recovery rates of larvae across the different tissues and time points are summarized in Table 1. The intestine was the first tissue in which the larvae were consistently detected, specifically within the

[Downloaded from ibj1.pasteur.ac.ir on 2026-10-16]

[DOI: 10.61882/ibj.4998]

Table 1. Average number of *T. leonina* larvae recovered from various tissues of Swiss albino mice infected with 1000 eggs at different time points

Dpi \ Tissues	Intestine	Kidney	Heart	Lung	Liver	Striated muscle	Spleen	Brain	Total	LR (%)
2	25 (±1.41)[a]	0	0	0	0	1 (±0.2)	0	0	26 (±1.5)	2.6
5	77 (±1.63)	0	0	0	0	0	0	0	77 (±1.64)	7.7
10	0	0	0	1 (±0.2)	3 (±0.86)	210 (±4.08)	0	0	214 (±4.1)	21.4
15	0	0	0	0	1 (±0.2)	125 (±2.05)	0	0	126 (±2.06)	12.6
20	0	0	0	2 (±0.46)	1 (±0.2)	120 (±2.01)	0	0	123 (±2.02)	12.3
30	0	0	0	3 (±0.81)	1 (±0.2)	121 (±2.02)	0	0	125 (±2.04)	12.5

[a]Standard deviation; LR: larvae recovery

intestinal wall (Fig. 1). Larvae were detectable in this tissue up to 5 dpi. Statistical analysis using the Kruskal-Wallis test showed a significant difference in larval recovery rates from intestinal tissue across the various time points ($p = 0.03$).

The highest number of larvae (210 ± 4.08) was found in striated muscle tissue at 10 dpi (Fig. 2). Larvae were present in these muscles at all days except for day 5, with a notable increase in numbers from day 10 onward. Larvae were also significantly recovered from lung tissue at 10, 20, and 30 dpi (Fig. 3). The liver was another tissue in which *T. leonina* larvae were detected (Fig. 4). The larvae were observed in this tissue at 10, 15, 20, and 30 dpi. Gross pathological changes in the infected mice included small linear hemorrhages in the liver parenchyma and, to a lesser extent, in the lungs. Microscopically, granulomatous inflammatory reactions were observed surrounding the trapped larvae under the intestinal mucosa and within other affected tissues. In contrast, tissue examination of the control group exhibited normal and unchanged tissue structure. In addition, fecal egg counts remained negative at 2 dpi.

DISCUSSION

The present study demonstrated that *T. leonina* larvae were predominantly localized in the striated muscles and intestinal walls of the infected mice, with no larvae detected in the kidneys, heart, spleen, or brain. Larva survival appeared limited, as most of them were eliminated in the early infection. However, the persistence of larvae in the tissues such as muscles suggest that mice can serve as viable paratenic hosts. Notably, pulmonary larval migration was observed in our study resembles patterns reported in human toxocariasis, which often involves the lungs [20].

Host-parasite dynamics are influenced by multiple factors, including host immunity, parasite virulence, and anatomical location[21-23]. In this study, the intensity of

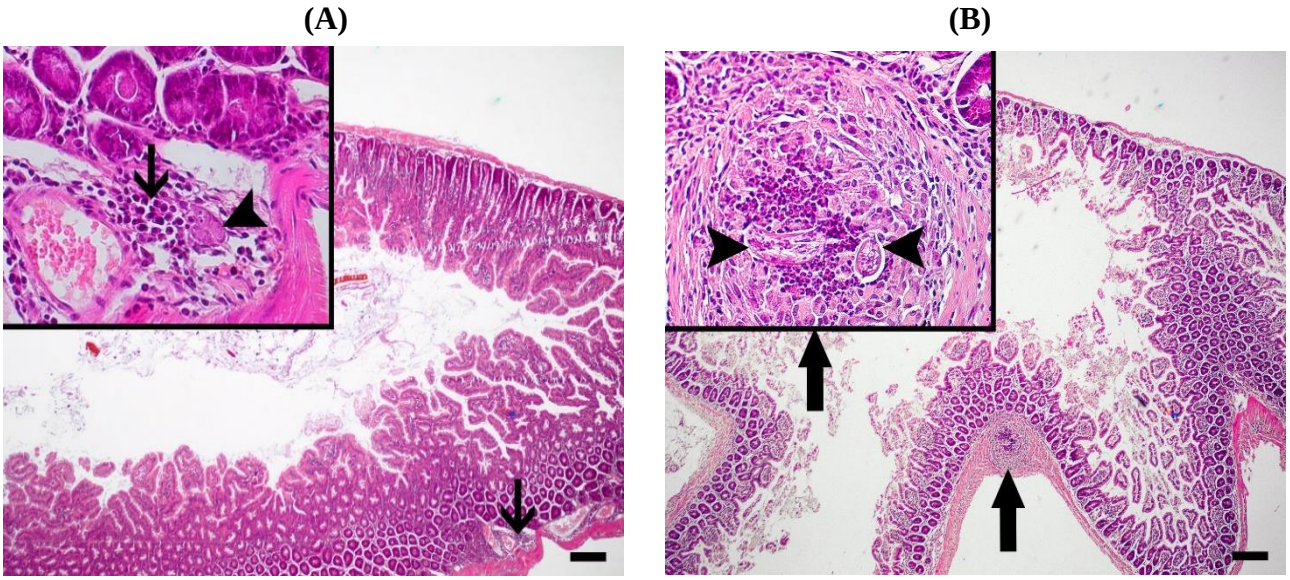

Fig. 1. Histological section of small intestine (H & E staining; scale bare: 200 µm; magnification 40×). Thin arrows, arrowheads, and thick arrows show accumulation of defense cells, parasite larvae, and granulomatous reaction, respectively.

[Downloaded from ibj1.pasteur.ac.ir on 2026-10-16]

[DOI: 10.61882/ibj.4998]

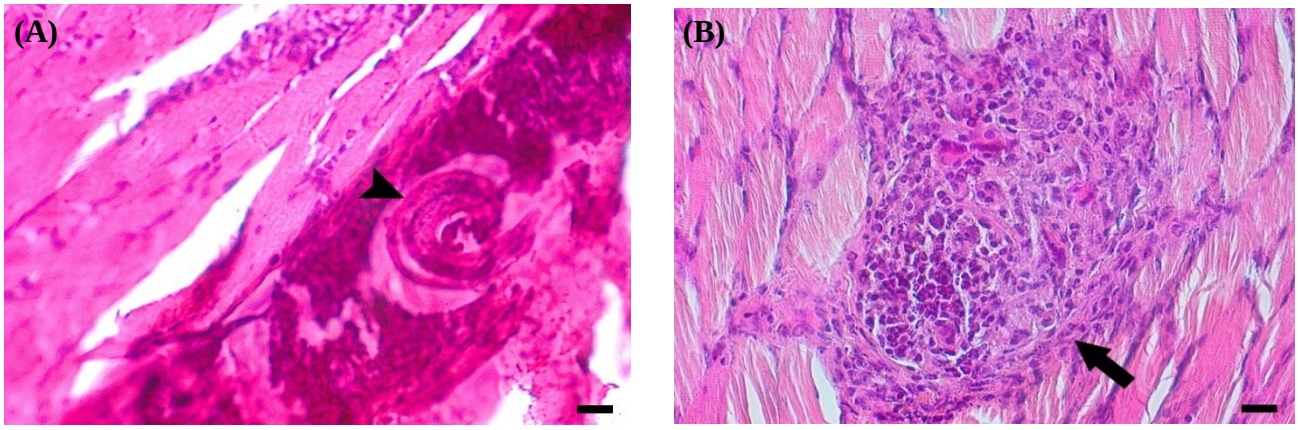

Fig. 2. Histological section of striated muscle (H & E staining; scale bar: 20 µm; magnification 400×). Arrowhead and arrow show parasite larvae and granulomatous reaction, respectively.

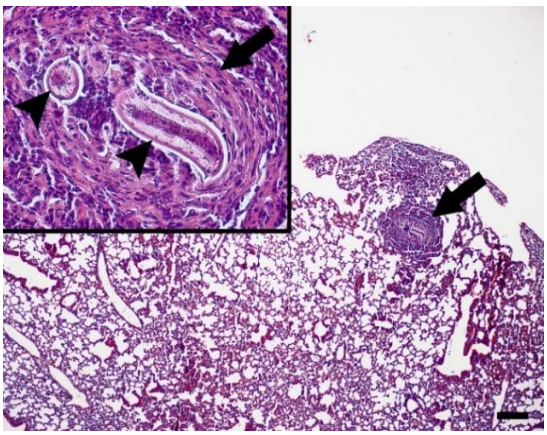

Fig. 3. Histological section of lung (H & E staining; magnification 40×). Arrowheads and thick arrows show granulomatous reaction and parasite larvae, respectively.

infection varied among tissues and individual mice and was correlated with the duration of infection—which was consistent with the prior studies[8]. The observed migration pathways and lesion patterns in mice also were in parallel with those described in human infections, suggesting a degree of translational relevance[24]. Variability in larval distribution across studies may be attributed to differences in host species, immune responses, and the rapid transit of eggs through the murine gastrointestinal tract.

Larvae numbers decreased in the lungs and intestines over time but increased in muscle tissue, supporting previous findings[6]. The absence of larvae in brain tissue aligns with the results reported by Okulewicz and colleagues[13]. At 2 dpi, larvae were most abundant in the intestines and leg muscles, while were absent in other tissues. By day 10, larvae were detected in the lungs, liver, and leg muscles, most prominently in muscle tissue. Larvae were persisted in the liver and muscles by the end of day 15 and found in the lungs, liver, and muscles from days 20 to 30. These findings contrast with those of Klockiewicz et al. who reported larvae presence in the lungs, spleen, intestines, and muscles by day 5 dpi[25] and with Prokopic and Figallova who observed larvae in the lungs (96%), sexual organs (84%), intestinal mucosa (81%), and skeletal muscles (100%) over a 135-day period, with peak accumulation in intercostal muscles by day 105[26].

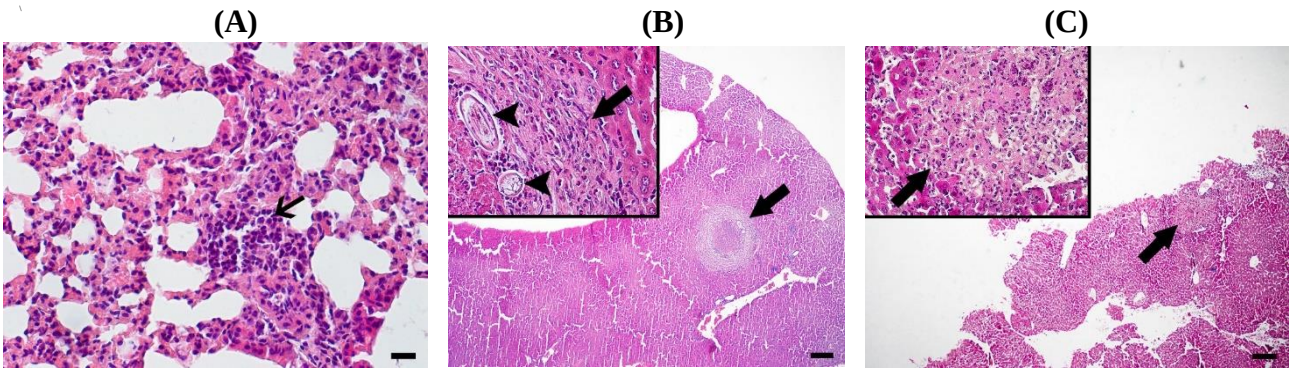

Fig. 4. Histological section of liver (H & E staining; magnification 40×). Thin arrows, thick arrows, and arrowheads show accumulation of defense cells, granulomatous reaction, and parasite larvae, respectively.

[Downloaded from ibj1.pasteur.ac.ir on 2026-10-16]

[DOI: 10.61882/ibj.4998]

Comparative studies of *T. transfuga* and *T. leonina* in mice/guinea pigs revealed distinct migration routes: *T. transfuga* larvae reached the brain, while *T. leonina* were localized in mesenteries/lymph nodes[27]. Small sample size was the limitation of this study. Future studies should explore alternative animal models (e.g. rats, gerbils, or immunodeficient mice) and incorporate molecular techniques (e.g. quantitative PCR and in situ hybridization) to enhance our understanding of larval migration patterns in Ascarididae species.

CONCLUSION

This study demonstrates that *T. leonina* larvae predominantly inhabit the striated muscles, followed by the intestinal wall, liver, and lungs. The highest larval counts observed in striated muscle tissue by the 10 dpi highlight the dynamic migratory behavior of the larvae within the host. The presence of granulomatous reactions and the accumulation of inflammatory cells confirm that Swiss albino mice serve as a paratenic host model for studying *T. leonina* and its implications for toxocariasis. Further research is needed to explore factors that may influence larval migration of the parasite.

DECLARATIONS

Acknowledgments

The authors would like to gratefully acknowledge the Deputy of Research of the Hamadan University of Medical Sciences, Hamadan, Iran, for their assistance and financial support. The authors did not use any artificial intelligence-assisted technologies in the production of the current work.

Ethical approval

This study was approved by the Ethics Committee of the Hamadan University of Medical Sciences, Hamadan, Iran (ethical code: IR.UMSHA.REC. 1400.094).

Consent to participate

Not applicable.

Consent for publication

All authors reviewed the results and approved the final version of the manuscript.

Authors' contributions

MS: conceptualization, investigation, methodology, data processing, and writing-original draft; AN: conceptualization, investigation, methodology, and data processing; FP, SZ, and HT: investigation, methodology, and formal analysis; AHM, MM, and SM: investigation, methodology, formal analysis, and writing-review & editing; MF: conceptualization, supervision, work administration, writing-original draft, and writing-review & editing.

Data availability

All relevant data can be found within the manuscript.

Competing interests

The authors declare that they have no conflict of interest.

Funding

This study is a part of the Ph.D. Thesis in Medical Parasitology and was financially supported by the Hamadan University of Medical Sciences, Hamadan, Iran [grant No. 140003182195].

Supplementary information

The online version does not contains supplementary material.

REFERENCES

1. Deplazes P, Eckert J, Mathis A, von Samson-Himmelstjerna G, Zahner H. Parasitology in veterinary medicine: Wageningen Academic; 2016.
2. Georgi JR, Georgi ME. Canine clinical parasitology. Lea & Febiger; 1991.
3. Rostami A, Riahi SM, Fallah Omrani V, Wang T, Hofmann A, Mirzapour A, et al. Global prevalence estimates of *Toxascaris leonina* infection in dogs and cats. Pathogens. 2020;9(6):503.
4. Hajipour N. A survey on the prevalence of *Toxocara cati*, *Toxocara canis* and *Toxascaris leonina* eggs in stray dogs and cats' faeces in Northwest of Iran: a potential risk for human health. Trop Biomed. 2019;36(1):143-51.
5. Fava NM, Cury MC, Santos HA, Takeuchi-Storm N, Strube C, Zhu X-Q, et al. Phylogenetic relationships among *Toxocara* spp. and *Toxascaris* sp. from different regions of the world. Vet parasitol. 2020;282:109133.
6. Okulewicz A, Lonc E, Borgsteede F. Ascarid nematodes in domestic and wild terrestrial mammals. Pol J Vet Sci. 2002;5(4):277-81.
7. Pawar R, Lakshmikantan U, Hasan S, Poornachandar A, Shivaji S. Detection and molecular characterization of ascarid nematode infection (*Toxascaris leonina* and *Toxocara cati*) in captive Asiatic lions (*Panthera leo persica*). Acta Parasitol. 2012;57(1):67-73.
8. Rostami A, Sepidarkish M, Ma G, Wang T, Ebrahimi M, Fakhri Y, et al. Global prevalence of *Toxocara* infection in cats. Adv Parasitol. 2020;109:615-39.
9. Sprent J. On the migratory behavior of the larvae of various *Ascaris* species in white mice: distribution of larvae in tissues. J Infect Dis. 1952;90(2):165-76.

[Downloaded from ibj1.pasteur.ac.ir on 2026-10-16]

[DOI: 10.61882/ibj.4998]

10. Sprent J. The life history and development of *Toxascaris leonina* (von Linstow 1902) in the dog and cat. Parasitology. 1959;49:330-71.
11. Hamilton C, Stafford P, Pinelli E, Holland C. A murine model for cerebral toxocariasis: characterization of host susceptibility and behaviour. Parasitology. 2006;132(6):791-801.
12. Azizi S, Oryan A, Sadjjadi S, Zibaei M. Histopathologic changes and larval recovery of *Toxocara cati* in experimentally infected chickens. Parasitol Res. 2007;102(1):47-52.
13. Okulewicz A, Perec-Matysiak A, Buńkowska K, Hildebrand J. *Toxocara canis*, *Toxocara cati* and *Toxascaris leonina* in wild and domestic carnivores. Helminthologia. 2012;49:3-10.
14. Barriga OO, Omar HM. Immunity to *Toxocara vitulorum* repeated infections in a rabbit model. Vet Immunol Immunopathol. 1992;33(3):249-60.
15. Sabry M. Epidemiological studies on toxocariasis in animals and man: PhD thesis (Zoonoses), Faculty of Veterinary Medicine, Cairo University; 1999.
16. Soulsby EJL. Helminths, arthropods and protozoa of domesticated animals. Ewp; 1982.
17. Taira K, Saeed I, Permin A, Kapel C. Zoonotic risk of *Toxocara canis* infection through consumption of pig or poultry viscera. Vet Parasitol. 2004;121:115-24.
18. Waindok P, Janecek-Erfurth E, Lindenwald DL, Wilk E, Schughart K, Geffers R, et al. *Toxocara canis*-and *Toxocara cati*-induced neurotoxocarosis is associated with comprehensive brain transcriptomic alterations. Microorganisms. 2022;10(1):177.
19. Scudamore CL. A practical guide to the histology of the mouse: John Wiley & Sons; 2014.
20. Llanes KKR, Besana CM, Paller VGV. Larval distribution, migratory pattern and histological effects of *Toxocara canis* in *Rattus norvegicus*. J Parasit Dis. 2019;43(4):679-85.
21. Ferrari N, Citterio CV, Lanfranchi P. Infracommunity crowding as an individual measure of interactive-isolationist degree of parasite communities: disclosing the effects of extrinsic and host factors. Parasit Vectors. 2016;9:88.
22. Mohtasebi S, Sazmand A, Zafari S, Verocai GG, Otranto D. Lungworms of non-ruminant terrestrial mammals and humans in Iran. Pathogens. 2023;12(6):795.
23. Zafari S, Mohtasebi S, Sazmand A, Bahari A, Sargison ND, Verocai GG. The prevalence and control of lungworms of pastoral ruminants in Iran. Pathogens. 2022;11(12):1392.
24. Pahari T, Sasmal N. Experimental infection of mice with *Toxocara canis* larvae obtained from Japanese quails. Int J Parasitol. 1990;20(2):263-4.
25. Okoshi S, Usui M. Experimental studies on *Toxascaris leonina*. IV. Development of eggs of three ascarids, *T. leonina*, *Toxocara canis* and *Toxocara cati*, in dogs and cats. Nihon Juigaku Zasshi. 1968;30(1):29-38.
26. Prokopic J, Figallova V. The migration of larvae of *Toxascaris leonina* (Linstow, 1909) in experimentlly infected white mice. Folia Parasitol. 1982;26(3):233-8.
27. Matoff K, Komandarev S. Comparative studies on the migration of the larvae of *Toxascaris leonina* and *Toxascaris transfuga*. Z F Parasitenkunde. 1965;25:538-55.

[Downloaded from ibj1.pasteur.ac.ir on 2026-10-16]

[DOI: 10.61882/ibj.4998]