FULL LENGTH	Iranian Biomedical Journal 25 (6): 417-425 November 2021

Calcitriol Treatment Attenuates Uric Acid-Induced Kidney Injury via Super Oxide Dismutase-1 (SOD-1) Upregulation and Fibrosis Reduction

Muhammad Mansyur Romi[1,2*], Nur Arfian[1], Wiwit Ananda Wahyu Setyaningsih[1], Rachma Greta Perdana Putri[3], Mohammad Juffrie[4] and Dwi Cahyani Ratna Sari[1]

[1]Department of Anatomy, Faculty of Medicine, Public Health and Nursing, Universitas Gadjah Mada, Yogyakarta, Indonesia; [2]Doctoral Program in Medical Sciences, Faculty of Medicine, Public Health and Nursing, Universitas Gadjah Mada, Yogyakarta, Indonesia; [3]Department of Anatomical Pathology, Faculty of Medicine, Universitas Ahmad Dahlan, Yogyakarta, Indonesia; [4]Department of Pediatrics, Faculty of Medicine, Public Health and Nursing, Universitas Gadjah Mada, Yogyakarta, Indonesia

Received 6 July 2020; accepted 4 January 2021; published online 20 October 2021

[Downloaded from ibj1.pasteur.ac.ir on 2026-10-17]

[DOR: 20.1001.1.1028852.2021.25.6.3.7]

[DOI: 10.52547/ibj.25.6.417]

ABSTRACTS

Background: Hyperuricemia induces nephropathy through the mediation of oxidative stress, tubular injury, inflammation, and fibrosis. The high uric acid level is associated with the reduction of vitamin D levels. However, the reno-protective effects of this vitamin in hyperuricemia condition remain unknown. This study aimed to elucidate calcitriol treatment in a uric acid-induced hyperuricemia mice model. **Methods**: Uric acid (125 mg/kg BW) was administered intraperitoneally for 7 (UA7) and 14 (UA14) days. Calcitriol (0.5 μg/kg BW) was intraperitoneally injected for the following seven days, after 14 days of uric acid induction (UA14VD7 group). The control group received NaCl 0.9%, by the same route. Serum creatinine was measured using calorimetric method, and uric acid levels were assessed using enzymatic calorimetric assay. Tubular injury and fibrosis were assessed using PAS and Sirius red staining. RT-PCR and qRT-PCR were carried out for the analyses of *SOD-1*, *Collagen*-1, and *TGF-β1* mRNA expression in the kidney. Immunostaining of SOD-1 was performed to detect its expression in the kidney. **Results**: Uric acid and creatinine levels markedly increased in UA14 groups, followed by an exacerbation of tubular injury. RT-PCR revealed the upregulation of *Collagen-1* and *TGF-β1*, along with the downregulation of *SOD-1*. Calcitriol treatment attenuated the injury with reducing uric acid and creatinine levels, as well as tubular injury. This was associated with lower *Collagen-1* and *TGF-β1* mRNA expression compared to the UA7 and UA14 groups. SOD-1 was upregulated in epithelial cells in the UA14VD7 group. **Conclusion**: Calcitriol treatment after uric acid induction may attenuate kidney injury through upregulation of *SOD-1* and downregulation of *Collagen-1* and *TGF-β1* gene expression. ***DOI: 10.52547/ibj.25.6.417***

Keywords: Fibrosis, Hyperuricemia, Kidney injury, Superoxide dismutase-1, Vitamin D

Corresponding Author: Muhammad Mansyur Romi
Department of Anatomy, Faculty of Medicine, Public Health, and Nursing, Universitas Gadjah Mada, Yogyakarta, Indonesia;
Tel.: (+62-274) 6492521 or (+62-818) 267380; Fax: (+62-274) 547730; E-mail: romi.mm@ugm.ac.id

INTRODUCTION

Chronic kidney disease has become one of the global health problems with increased morbidity and mortality[1]. Hyperuricemia was related to CKD as up to 60% of gout patients were suffered from mild to moderate renal dysfunction, and nearly 25% of these patients developed into CKD[2,3]. In addition, the incidence of hyperuricemia was reported to be increasing in developing as well as

List of Abbreviations:
BW, body weight; **CKD,** chronic kidney disease; **GAPDH,** glyceraldehyde-3-phosphate dehydrogenase; **GSH,** glutathione; **NADPH,** nicotinamide adenine dinucleotide phosphate; **NFκB,** nuclear factor kappa B; **PAS,** periodic acid-Schiff; **qRT-PCR,** real-time reverse transcription PCR; **RAAS,** renin-angiotensin-aldosterone system; **ROS,** reactive oxygen species; **SOD-1,** super oxide dismutase type 1; **URAT1,** urate transporter 1; **VDR,** vitamin D receptor

developed countries[4–6]. A previous study has reported that uric acid has a role in renal inflammation, endothelial dysfunction, and CKD[7]. Even in children and teenagers, a cohort study showed that hyperuricemia is a risk factor for the progression of CKD[8]. In this condition, a xanthine oxidase inhibitor is administrated in order to ameliorate hyperuricemia and inhibit CKD progression[9]. Filtered urate in hyperuricemia condition is absorbed by epithelial cells, thus inducing tubular injury[7]. The nephropathy hyperuricemia is associated with fibroblast expansion, TGF-β1, and endothelin 1 upregulation[10], and is epithelial to mesenchymal transition with the activation of Wnt5a/Ror2 gene expression[11].

Vitamin D deficiency is considered as a non-conventional risk factors of CKD, since most CKD patients were reported as vitamin D deficient[12-14]. Therefore, an adequate vitamin D level is a potential therapeutic target for CKD patients[15]. Vitamin D metabolism involves skin, liver, and kidney to produce active biological form, 1,25-dihydroxy vitamin D3 [$1,25(OH)_2D_3$], or calcitriol[16]. Reno-protective effect of vitamin D may associate with the upregulation of VDR in podocyte after the administration of vitamin D in a mouse model of diabetic nephropathy[17]. Vitamin D reduces inflammation and macrophage infiltration[18] and attenuates tubular injury and apoptosis in a kidney fibrosis model[19]. This vitamin also decreases endothelial dysfunction by inducing endothelial nitric oxide synthase activation in endothelial cells culture[20]. Vitamin D has antioxidant activity and is able to alleviate ROS formation in diabetic conditions[20,21].

Some studies have explored a correlation between hyperuricemia and vitamin D deficiency. Sodium urate infusion has been demonstrated to suppress calcitriol synthesis in rats. An experimental study has reported the reduced levels of $1,25(OH)_2D$ and 1-αhydroxylase expression due to the increase of uric acid level[22]. Elevation of uric acid has been linked to lower $1,25(OH)_2D$ levels in individuals who suffered from gout, as well as kidney disease[23,24]. Some published data have indicated that elevated uric acid levels were inversely related to 25(OH)D levels[25], whereas other investigations have found no such association[26]. Reduction of uric acid level may relate to the attenuation of inflammation and vascular injury induced by uric acid[27]. Calcitriol treatment for seven days attenuates myofibroblast formation and collagen expression in a unilateral ureteral obstruction model[28]. However, there is still limited research on the effect of calcitriol administration in kidney injury after uric acid induction. Therefore, this study was aimed to elucidate vitamin D supplementation in reducing kidney injury induced by uric acid.

MATERIALS AND METHODS

Hyperuricemia model in mice

A total of 24 Swiss background mice (4 months old and 30-35 g) were divided into four groups: control, uric acid induction for seven days (UA7), uric acid induction for 14 days (UA14), and uric acid induction for 14 days + vitamin D injection for seven days (UA14VD7). Hyperuricemia was induced in UA7, UA14, and UA14VD7 groups by daily intraperitoneal administration of uric acid (125 mg/kg BW, diluted in NaOH 0.15-0.2 M; Sigma, U25G-26, Germany), for seven days. The procedure was applied as described before with some modifications[7,10]. In UA14VD7 group, calcitriol (Cayman®, Cat. No. 9000683, USA; with the dose of 0.5 μg/kg BW) was administered intraperitoneally for the following seven days (at day 15) after 14 days of uric acid induction. Calcitriol injection was prepared by dissolving calcitriol powder in 0.2% ethanol, followed by dilution in NaCl 0.9%, to obtain the exact dose for each mouse. Control group received intraperitoneal NaCl 0.9% injection for 21 days.

Blood sampling and organ harvesting

Before terminating the mice, blood was collected from retro-orbital vein for the measurement of creatinine and uric acid levels. Mice were anaesthetized using ketamine before opening up the thorax and abdomen in deep anaesthetization condition. Perfusion method was performed using NaCl 0.9% administered from cardiac apex. Both kidneys of each mouse were removed; left kidney was stored in a normal buffer formalin solution for histological examination, and right kidney was kept in RNA preservation solution (Favorgen, FATRR 001, Taiwan) for the RNA extraction.

PAS staining for tubular injury assessment

Four micrometer thickness of paraffin sections were deparaffinized and then stained using PAS to evaluate tubular injury. Tubular injury was scored according to the pathological appearances of tubular injury such as loss of brush border, tubular epithelial effacement, and intraluminal cast formation in 15 random areas, non-overlapping fields (magnification 200×). The lesions were graded using a scale from 0 to 4 with the following interpretations: 0: normal; 1: the injury involves >25% of the field (for tubular injury) and glomerulus; 2: the injury involves 25% to 50%; 3: the injury involves 50% to 75%; and 4: extensive injury that involves <75%[29].

[Downloaded from ibj1.pasteur.ac.ir on 2026-10-17]
[DOR: 20.1001.1.1028852.2021.25.6.3.7]
[DOI: 10.52547/ibj.25.6.417]

[Downloaded from ibj1.pasteur.ac.ir on 2026-10-17]

[DOR: 20.1001.1.1028852.2021.25.6.3.7]

[DOI: 10.52547/ibj.25.6.417]

Sirius red staining

Four-micrometer sections were deparaffinized and then stained using Pico-Sirius red solution. The red stained paraffin sections were observed as the presence of interstitial fibrosis. Area fraction of interstitial fibrosis was quantified from randomly chosen 10-15 images (with 400× magnification), which were captured using OptiLab-installed microscope (Olympus, CX22, China).

Immunohistochemical staining of SOD-1

Thick paraffin slides (4 µm) were deparaffinized for immunohistochemical staining. The slides were heated in a citrate buffer (pH 6), incubated with 3% H_2O_2 in PBS for 5 minutes to inhibit endogenous peroxidase and then continued by the incubation in a blocking reagent to reduce non-specific background staining (background sniper, Star Trek IHC kit, BioCare 2, BioMed Research International Medical, USA). Subsequently, the samples were incubated in SOD-1 antibody as a primary antibody (1:100; Bioss; bs-10216R, USA) at 4 ºC overnight. At the following day, the slides were washed with PBS prior to secondary antibody incubation using Streptavidin HRP labelled secondary antibody (Star Trek IHC kit) at room temperature for 1 hour. Diaminobenzidine solution (Star Trek IHC kit) was used to visualize the staining.

RNA extraction, RT-PCR, and qRT-PCR,

Total RNA was extracted from kidney tissue samples using RNAiso PLUS (Genezol, GZR100). RNA samples (1 µg) was reverse-transcribed using ReverTraAce reverse transcriptase (TRT-101, Toyobo, Japan) in a 20-µL reaction containing random primer, reverse transcriptase enzyme, and buffer. The cDNA synthesis procedure was as per the manufacture's guidelines. RT-PCR was performed to examine the mRNA expression of the genes using the appropriate primer sets (Table 1). RT-PCR was performed using Go Tag Green Mastermix (M7122, Promega, USA) by adding 3 µL of cDNA as template. Then the following thermal cycles were implemented to amplify the target DNA: initial denaturation at 94 ^{o}C for 2 min, followed by 35 cycles of denaturation at 94 ^{o}C for 10 s, annealing at 60 ^{o}C for 20 s, extension at 72 ^{o}C for 1 min, and the final extension at 72 ^{o}C for 10 min. The mRNA expression of *TGF-β1* was assessed using qRT-PCR, which was used to amplify the *TGF-β1* mRNA expression. The following condition was also used to amplify *TGF-β1* mRNA expression: initial denaturation at 94 ^{o}C for 2 min, followed by 35 cycles of denaturation at 94 ^{o}C for 10 s, annealing at 60 ^{o}C for 20 s, extension at 72 ^{o}C for 1 min, and the final extension at 72 ^{o}C for 10 min.

Statistical analysis

The data distribution was analyzed using Kolmogorov-Smirnov test. Continuous variables were analyzed using independent sample t-test or ANOVA for normally distributed data, and Mann-Whitney test for data not normally distributed. The simple regression and Spearman's tests were employed to test correlation. Values of $p < 0.05$ were considered statistically significant. All statistical analyses were performed using SPSS software version 17.0 (SPSS Inc., Chicago, IL, USA).

Ethical statement

The above-mentioned animal procedures protocols were approved by the Medical and Health Research Ethics Committee of Faculty of Medicine, Public Health and Nursing, Universitas Gadjah Mada, Indonesia (ethical code: KE/FK/0412/EC/2019).

RESULTS

Calcitriol treatment attenuated uric acid-induced tubular injury

Serum uric acid levels were found to be significantly higher in UA7 ($p = 0.001$) and UA14 ($p = 0.002$) groups compared to the control. Calcitriol treatment after the uric acid induction in UA14VD7 group significantly reduced serum uric acid level compared to UA14 ($p = 0.002$) groups, although it was still significantly higher compared to the control group (Fig. 1A). Furthermore, UA7 and UA14 groups showed significantly higher serum creatinine levels compared to the control ($p < 0.05$), indicating abnormal renal functions. Calcitriol treatment showed to significantly ameliorate the serum creatinine level after uric acid induction (Fig. 1B). Histological analysis of PAS staining demonstrated the injury of tubular epithelial cells in UA7 and UA14 groups (Fig. 1C and 1D). UA14 groups displayed the highest

Table 1. List of primer sequences

Genes	Forward sequences (5′ → 3)	Reverse sequences (5′ → 3)
SOD-1	GCATTCCATCATTGGCCGTA	TTTCCACCTTTGCCCAAGTCA
Collagen-1	ATGCCGCGACCTCAAGATG	TGAGGCACAGACGGCTGAGTA
TGF-β1	TTCCGCTGCTACTGCAAGTCA	GGGTAGCGATCGAGTGTCCA
GAPDH	TTGCTGTTGAAGTCGCAGGAG	TGTGTCCGTCGTGGATCTGA

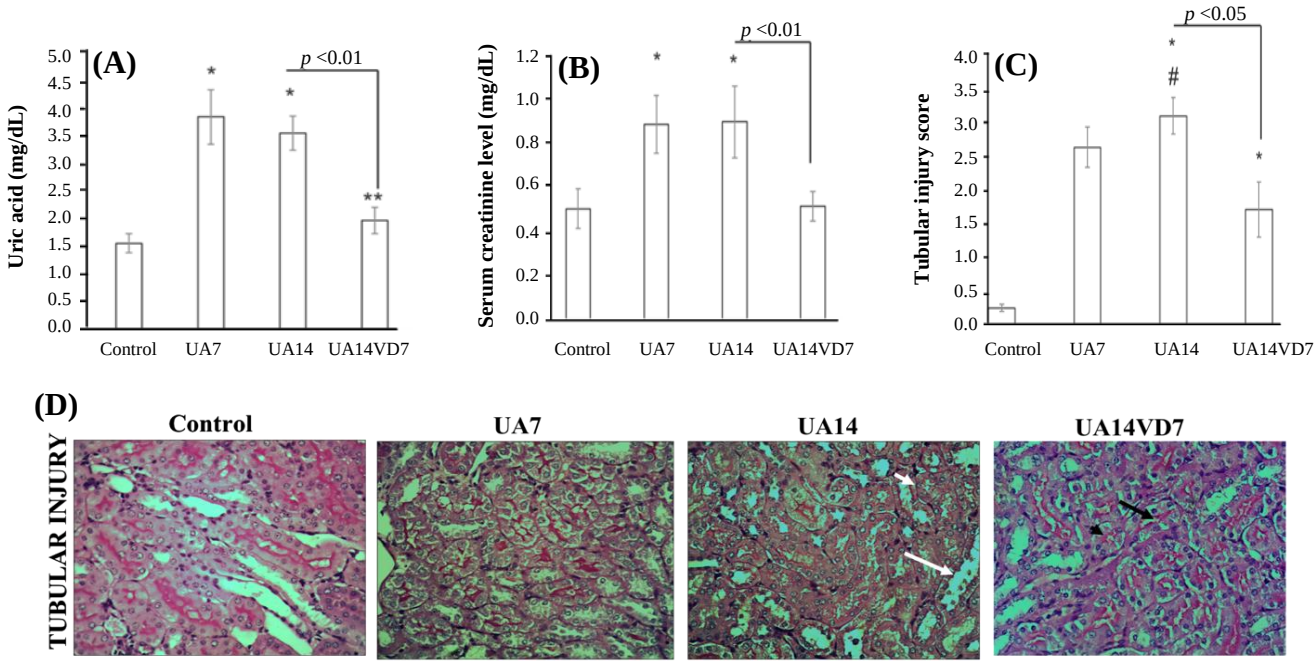

Fig. 1. Serum uric acid level, serum creatinine level, and tubular injury in uric acid-induced hyperuricemia model mice. (A) Serum uric acid levels, (B) serum creatinine levels, and (C) tubular injury score in the control, UA7, UA14, and UA14VD7 groups. A significant increase in the UA7 and UA14 groups was found in all parameters, whereas calcitriol treatment in UA14VD7 group significantly decreased these parameters. (D) Representative histological images of PAS staining, demonstrating the appearance of tubular injury in all groups. Tubular injury was marked by epithelial cells effacement and brush border loss (white arrows). The regeneration of brush border was found in the UA14VD7 group (black arrows). $^{*}p < 0.05$ vs. control, $^{**}p < 0.01$ vs. control, $^{\#}p < 0.05$ vs. UA7

tubular injury score with epithelial cell effacement and brush border loss. Following the calcitriol treatment, the tubular injury was attenuated as evidenced by the initiation of regeneration process and brush border appearance in the PAS staining. Tubular injury score was significantly lower in UA14VD7 group compared to UA7 and UA14.

Calcitriol treatment affected collagen accumulation and *Collagen-1* and *TGF-β1* gene expression

To assess the interstitial fibrosis of kidney, we performed Sirius red staining to observe the collagen deposit and extracellular matrix accumulation in tubular basement membranes. UA14 group demonstrated positive red staining in the interstitial areas and thickening of basement membrane that characterized interstitial fibrosis. UA14VD7 group, however, showed less positive staining in the interstitial areas (Fig. 2A). *Collagen-1* upregulated in UA7 and UA14 groups with significantly higher mRNA expression when compared to the control (p = 0.001, Fig. 2B and 2C). Furthermore, UA14VD7 group showed significantly lower *Collagen-1* mRNA expression compared to UA14 group (p = 0.000). We also examined the mRNA expression of *TGF-β1*, a profibrotic factor. Our results revealed significantly higher *TGF-β1* mRNA expression in UA14 group compared to the control (p = 0.000). Meanwhile, downregulation of *TGF-β1* was found in UA14VD7 group with significantly lower *TGF-β1* mRNA expression compared to UA14 (p = 0.032; Fig. 2D).

Calcitriol treatment increased the SOD-1 expression levels

The quantification of *SOD-1* mRNA expression using RT-PCR revealed significantly lower expression in UA14 group compared to the control (p = 0.003, Fig. 3A and 3B). However, calcitriol treatment after uric acid induction demonstrated significantly higher *SOD-1* mRNA expression UA14VD7 group (p = 0.008) compared to the UA14 group. In addition, immunostaining of SOD-1 in the control group showed positive staining in tubular epithelial cells (Fig. 3C). In contrast, UA7 and UA14 groups demonstrated less positive staining of SOD-1 in epithelial cells. Calcitriol-treated group, UA14VD7, demonstrated much more positive staining compared to the UA14 group.

DISCUSSION

This study revealed that calcitriol treatment might have beneficial effect on reducing uric acid level,

[Downloaded from ibj1.pasteur.ac.ir on 2026-10-17]
[DOR: 20.1001.1.1028852.2021.25.6.3.7]
[DOI: 10.52547/ibj.25.6.417]

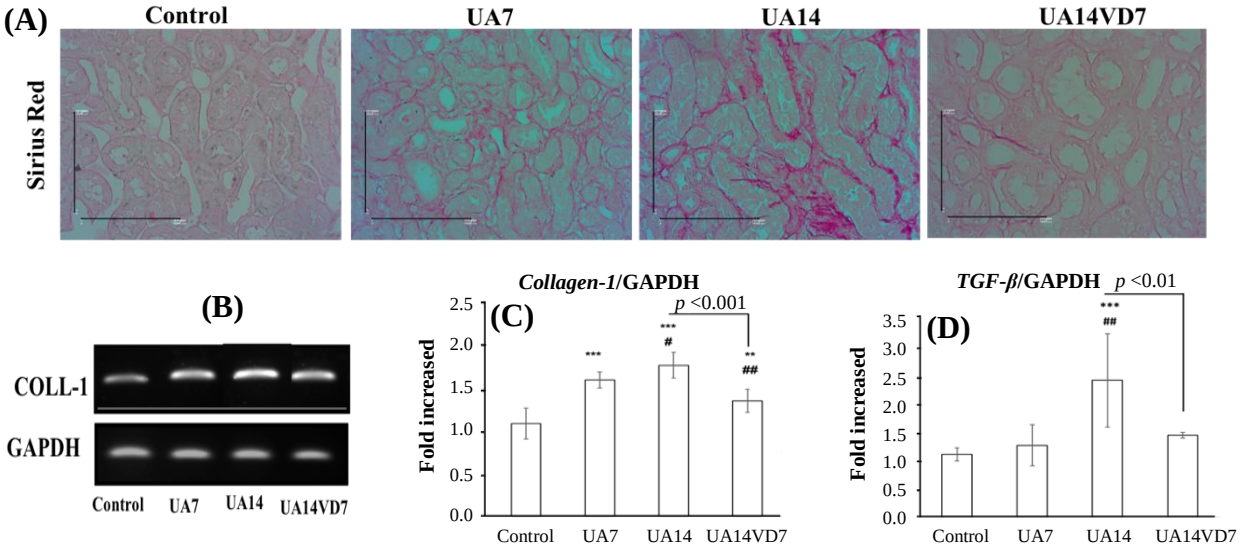

Fig. 2. Collagen accumulation assessment using Sirius red staining and the mRNA expressions of *Collagen-1* and *TGF-β1* in the kidney of uric acid-induced hyperuricemia model mice. (A) Representative histological images of Sirius red staining, suggesting the presence of collagen accumulation in the interstitial areas. The UA14 group showed positive red staining of Sirius red, indicating interstitial fibrosis. (B) Representative images of gel electrophoresis from RT-PCR products of *Collagen-1* (Coll-1) and *GAPDH*. (C) Relative quantification of the mRNA expressions of *Collagen-1* using densitometry analysis. The expression was normalized to the expression of *GAPDH*, a housekeeping gene. *Collagen-1* showed to be downregulated in the UA14VD7 group. (D) Relative quantification of the mRNA expressions of *TGF-β1* using qRT-PCR analysis. $^{**}p < 0.01$ vs. control, $^{***}p < 0.001$ vs. control, $^{\#}p < 0.05$ vs. UA7, $^{\#\#}p < 0.01$ vs. UA7

serum creatinine level, and tubular injury after uric acid induction. Uric acid has been known as an independent risk factor for the development of cardiovascular and renal diseases, as well as a predictor of renal injury[30,31]. One study has reported the association between vitamin D insufficiency and high uric acid level in many diseases, including type 2 diabetes mellitus[32]. Another study has disclosed that vitamin D insufficiency was significantly related to elevated uric acid among postmenopausal, but not premenopausal Chinese Han Women[25]. Patients with hyperuricemia was reported to have lower serum vitamin D level compared to individuals whose uric acid level was normal, particularly in middle-aged and elderly population[33]. It has also been reported that uric acid suppresses 1 alpha hydroxylase, an essential enzyme for converting 25 (OH) vitamin D to its active form, 1,25(OH)2[34]. Research using *in vitro* and *in vivo* approach has demonstrated that the suppression of 1 alpha hydroxylase may lead to lower 1,25(OH)2D and higher parathyroid hormone levels, which is mediated by the NFκB pathway[35]. Due to the close correlation between serum uric acid level and vitamin D level, our result revealed calcitriol treatment attenuated uric acid induced kidney injury.

The present study demonstrated the amelioration of tubular injury after calcitriol treatment. Tubular cells reabsorb most of the urate in proximal tubules[36], which is mediated by a specific transporter, such as URAT1 transporter, then induces fibronectin secretion and extracellular matrix production[7]. Tubular epithelial cells secret profibrotic growth factors, e.g. platelet-derived growth factor, connective tissue growth factor, and *TGF-β1*, which stimulate fibrosis[37]. The renoprotective effects of vitamin D may be mediated by several mechanisms, including protection of podocytes, suppression of RAAS, attenuation of inflammation by reducing NF-κB expression, and fibrosis[38]. Our study exhibited the downregulation of *Collagen-1* and *TGF-β1* mRNA expression after calcitriol treatment. A previous study has shown the mechanisms of vitamin D in the reduction of fibrosis by preventing TGF-β Smad activation through pSmad3 inhibition[39]. Furthermore, vitamin D induces hepatocyte growth factor, an inhibitor of *TGF-β1* signalling, and further suppresses myofibroblast activation and epithelial to mesenchymal transition[40]. The final effect of this process is the reduction of extracellular matrix production, i.e. collagen type I, collagen type III, and fibronectin. Moreover, vitamin D inhibits RAAS through suppressing renin transcription[41]. On the other hand, uric acid activates RAAS[42]. We assumed that the protective effect of vitamin D after uric acid induction might be modulated by its ability in reducing RAAS activation and extracellular matrix production.

[Downloaded from ibj1.pasteur.ac.ir on 2026-10-17]
[DOR: 20.1001.1.1028852.2021.25.6.3.7]
[DOI: 10.52547/ibj.25.6.417]

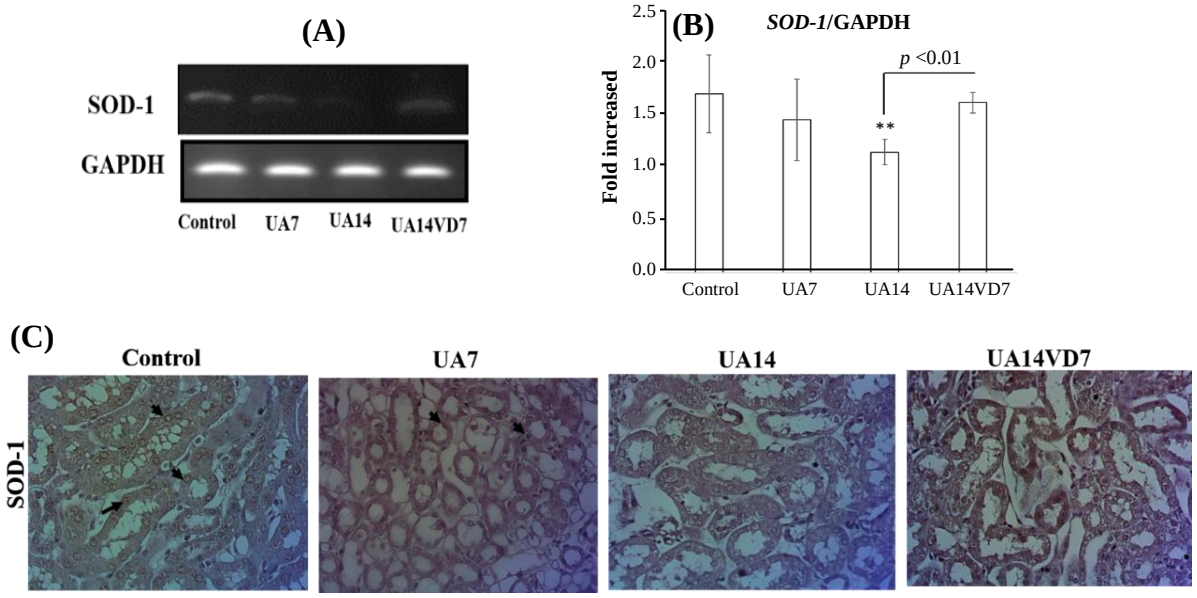

Fig. 3. The mRNA expression of *SOD-1* and immunohistochemical staining of *SOD-1* in the kidney of uric acid-induced hyperuricemia model mice. (A) Representative images of gel electrophoresis from RT-PCR products of *SOD-1* and *GAPDH*. (B) Relative quantification of the mRNA expressions of *SOD-1* using densitometry analysis. The expression was normalized to the expression of *GAPDH*, a housekeeping gene. *SOD-1* showed to be upregulated in the UA14VD7 group. (C) Immunostaining of *SOD-1* demonstrated positive staining in epithelial cells (black arrows). $^{**}p < 0.01$ vs. control

Inhibition of RAAS might associate with the inhibition of collagen type 1 expression in the kidney[43,18]. Angotensin II increases glomerular capillary pressure, and induces inflammatory cytokine production and profibrotic factor[44], which is followed by extracellular matrix production and podocyte damage[45]. It also induces procollagen type 1 mRNA expression and fibronectin in mesangial cells[46]. According to these facts, we speculated that renoprotective effect of calcitriol after uric acid induction may also be modulated by inhibition of RAAS.

The vitamin D through VDR activation inhibits RAAS and may facilitates the reno-protective effect of vitamin D. VDR is expressed in many tissues, such as small intestine, bone, parathyroid, retina, pituitary gland, pancreas, ovaries, spleen, skin, and some nerve tissues. In kidney, VDR is present in proximal and distal tubular epithelial cells, glomerular parietal cells, and collective duct cells[38,47]. Vitamin D is known to improve glomerulosclerosis by binding to VDR and inhibiting the stimulation of RAAS pathway, which result in the inhibition of hemodynamic changes in glomerular volume and mesangial proliferation[48]. Vitamin D attenuated fibrosis and apoptosis in kidney fibrosis model in mice by inhibiting inflammation and collagen production[19,49]. An *in vitro* study in lung fibroblast and epithelial cells showed the inhibition of fibronectin and *Collagen-1* expression in cells treated with *TGF-β1*[50]. Our findings revealed that the downregulation of *TGF-β1* and *Collagen-1* mRNA expression after calcitriol treatment in uric acid-induced hyperuricemia model is consistent with other studies that reported inhibition or reduction of *TGF-β1* signaling after Vitamin D treatment[39,40].

This study demonstrated the potential effect of vitamin D as an antioxidant on the upregulation of *SOD-1* expression in epithelial cells, which was associated with reduced tubular injury. SOD, one of the antioxidant enzymes besides catalase and GSH peroxidase[51], is the first line cellular antioxidant in many cells[52]. Although uric acid is believed to serve as an antioxidant[53], uric acid was proven to induce much more damage in vascular endothelial compared to its antioxidant effect[54]. Oxidative stress plays a role in this process, finally leading to an inflammation. Elevation of uric acid also induces ROS production in endothelial cells of the vessels, then releasing inflammatory mediators such as monocyte chemoattractant protein-1, IL-6, and TNF-α[54]. Many studies have displayed the antioxidants effects of vitamin D. Vitamin D administration reduced ROS formation with NADPH oxidase supression in diabetic mice[20,21]. Lipid peroxidation was also reduced by vitamin D administration, which is also associated with the increased SOD activity in mice[55–57]. In kidney, the

[Downloaded from ibj1.pasteur.ac.ir on 2026-10-17]
[DOR: 20.1001.1.1028852.2021.25.6.3.7]
[DOI: 10.52547/ibj.25.6.417]

antioxidant effect of vitamin D may be mediated by NADPH oxidase inhibition and cytosolic SOD upregulation[58]. Other study also reported increasing SOD activity and GSH level in renal tissue after pretreatment with vitamin D[59]. Study in clinical setting of hemodialysis patients also indicated that VDR activation with paricalcitol reduced oxidative stress markers (malondialdehyde and protein carbonyl groups) and incresed antioxidant enzymes (GSH, catalase, and SOD activities)[60]. This study has not elucidated inflammation and inflammatory mediator expression. Due to important role of inflmmatory meditors in this model, elucidating the expression of infalmmation and innflammatory mediators may give better understanding in the future.

In conclusion, administration of calcitriol after uric acid induction may attenuate kidney injury through the upregulation of SOD-1 and downregulation of *Collagen-1* and *TGF-β1* gene expression.

CONFLICT OF INTEREST. None declared.

ACKNOWLEDGMENTS

The authors would like to deliver the greatest gratitude to Mr. Mulyana (Department of Anatomy, Faculty of Medicine, Public Health, and Nursing, Universitas Gadjah Mada, Indonesia) for his technical assistance in laboratory during the study. This research work was funded by Penelitian Dasar PT and Dana Masyarakat, Faculty of Medicine, Public Health and Nursing University Gadjah Mada Yogyakarta, Indonesia (number 3593/UN1/FK-KMK.1/PD.1/ PT/2019).

REFERENCES

1. Francois H, Jacquet A. Emerging strategies to preserve renal function. *Journal of nephrology* 2011; **24**: 131-141.
2. Berger L, Yu T. Renal Function in Gout . IV . An Analysis of 524 Gouty Subjects Including Long-Term. *American journal of medicine* 1975; **59**(5): 605-613.
3. Talbott JH, Terplan KL. The kidneys in gout. *British medical journal* 1963; **1**(5332): 700.
4. Ricotti R, Genoni G, Giglione E, Monzani A, Nugnes M, Zanetta S, Castagno M, Marolda A,Bellomo G, Bona G, Bellone S, Prodam F. High-normal estimated glomerular filtration rate and hyperuricemia positively correlate with metabolic impairment in pediatric obese patients. *PLoS one* 2018; **13**(3):e0193755.
5. Song P, Wang H, Xia W, Chang X, Wang M, An L. Prevalence and correlates of hyperuricemia in the middle-aged and older adults in China. *Scientific reports* 2018; **8**(1): 1-9.
6. Jin M, Yang F, Yang I, Yin Y, Luo JJ, Wang H, Yang X. Uric Acid, hyperuricemia and vascular diseases. *Frontiers in bioscience* 2012; **17**: 656-669
7. Yang Z, Xiaohua W, Lei J, Ruoyun T, Mingxia X, Weichun H, Li F, Ping W, Junwei Y. Uric acid increases fibronectin synthesis through upregulation of lysyl oxidase expression in rat renal tubular epithelial cells. *American journal of physiology-renal physiology* 2010; **299**(2): 336-346.
8. Rodenbach KE, Schneider MF, Furth SL, Moxey-Mims MM, Mitsnefes MM, Weaver DJ, Warady BA, Schwartz GJ. Hyperuricemia and progression of CKD in children and adolescents: the chronic kidney disease in children (CKD) cohort study. *American journal of kidney diseases* 2016; **66**(6): 984-992.
9. Pisano A, Cernaro V, Gembillo G, D'Arrigo G, Buemi M , Bolignano D. Xanthine oxidase inhibitors for improving renal function in chronic kidney disease patients : an updated systematic review and meta-analysis. *International journal of molecular sciences* 2017; **18**(11): 2283.
10. Romi MM, Arfian N, Tranggono U, Setyaningsih WAW, Sari DCR. Uric acid causes kidney injury through inducing fibroblast expansion, Endothelin-1 expression, and inflammation. *BMC Nephrology* 2017; **18**(1): 326.
11. Setyaningsih WAW, Arfian N, Suryadi E, Romi MM, Tranggono U, Sari DCR. Hyperuricemia induces Wnt5a/Ror2 gene expression , epithelial–mesenchymal transition (EMT), and kidney tubular injury in mice. *Iranian journal of medical sciences* 2018; **43**(2): 164-173.
12. Patel T, Singh AK. Role of vitamin D in chronic kidney disease. *Semin nephrol*ogy 2010; **29**(2): 113-121.
13. Goncalves A, Gleize B, Roi S, Nowicki M, Dhaussy A, Huertas A, Amiot M, Reboul E. Fatty acids affect micellar properties and modulate vitamin D uptake and basolateral. *Journal of nutritional biochemistry* 2013; **24**(10):1751-1757.
14. Jean G, Souberbielle JC, Chazot C. Vitamin D in chronic kidney disease and dialysis patients. *Nutrients* 2017; **9**(4): 328.
15. Jhee JH, Kim H, Park S, Yun H, Jun S, Kee YK, Yoon C, Park JT, Han SH, Kang S, Yoo TH. Vitamin D deficiency is significantly associated with depression in patients with chronic kidney disease. *PLoS one* 2017; **12**(2): e0171009.
16. Wimalawansa SJ, Razzaque DMS, Al-daghri NM. Calcium and vitamin d in human health: hype or real? *Journal of steroid biochemistry and molecular biology* 2018; **180**: 4-14.
17. Trohatou O, Tsilibary EF, Charonis A, Iatrou C, Drossopoulou G. Vitamin D3 ameliorates podocyte injury through the nephrin signalling pathway. *Journal of cellular and molecular medicine* 2017; **21**(10): 2599-2609.
18. Li YC. Renoprotective effects of vitamin D analogs. *Kidney international* 2010; **78**(2):134-139.
19. Arfian N, Muflikhah K, Soeyono SK, Sari DCR,

[Downloaded from ibj1.pasteur.ac.ir on 2026-10-17]
[DOR: 20.1001.1.1028852.2021.25.6.3.7]
[DOI: 10.52547/ibj.25.6.417]

Tranggono U, Anggorowati N, Romi MM. Vitamin D attenuates kidney fibrosis via reducing fibroblast expansion, inflammation, and epithelial cell apoptosis. *Kobe journal of medical science* 2016; **62**(2): E38-E44.
20. Labudzynskyi D, Latyshko N, Gudkova O. Vitamin D(3) contribution to the regulation of oxidative metabolism in the liver of diabetic mice. *Ukrainian biochemical journal* 2015; **87**(3): 75-90.
21. Kono K, Fujiii H, Nakai K, Goto S, Kitazawa R, Kitazawa S, Shinohara M, Hirata M, Fukugawa M, Nishi S. Anti oxidative effect of vitamin D analog on incipient vascular lesion in non-obese type 2 diabetic rats. *American journal of nephrology* 2013; **37**(2):167-174.
22. Hsu CH, Patel SR, Young EW, Vanholder R. Effects of purine derivatives on calcitriol metabolism in rats. *American physiological society* 1991; **91**(4-2): F596-F601.
23. Takahashi S, Yamamoto T, Moriwaki Y, Tsutsumi Z, Yamakita J, Higashino K. Decreased serum concentrations of 1,25(OH)2-Vitamin D3 in patients with gout. *Advances in experimental medicine and biology* 1998; **431**: 57-60.
24. Vanholder R, Patel S, Hsu CH. Effect of uric acid on plasma levels of 1,25(OH)2D in renal failure. *American society of nephrology* 1993; **1**: 1035-1038.
25. Peng H, Li H, Li C, Chao X, Zhang Q, Zhang Y. Association between vitamin D insufficiency and elevated serum uric acid among middle-aged and elderly Chinese Han Women. *PLoS one* 2013; **8**(4): e61159.
26. Barceló A, Piérola J, Peña D, De la Peña M, Sánchez-de-la-Torre M, Montserrat JM, Marín JM, Duran J, Arqué M, Bauça JM, Barbé F. Vitamin D status and parathyroid hormone levels in patients with obstructive sleep apnea. *Respiration* 2013; **86**(4): 295-301.
27. Haryono A, Nugrahaningsih DAA, Sari DCR, Romi MM, Arfian N. Reduction of serum uric acid associated with attenuation of renal injury , inflammation and macrophages M1 / M2 ratio in hyperuricemic mice model. *Kobe journal of medical science* 2018; **64**(3): 107-114.
28. Arfian N, Budiharjo S, Kencana SMG, Susanto EH, Suhardi DY, Pramudita BD, Sari DCR, Romi MM (19-20 October 2018). Vitamin D reduces myofibroblast formation and collagen 1 expression through upregulating enos expression in kidney fibrosis model in mice. International Conference on Bioinformatics, Biotechnology, and Biomedical Engineering (BIOMIC, Yogyakarta, Indonesia. https://ieeexplore.ieee.org/ document/8610552.
29. Inazaki K, Kanamaru Y, Kojima Y, Sueyoshi N, Okumura J, Kaneko K, Yamashiro Y, Ogawa H, Nakao A. Smad3 deficiency attenuates renal fibrosis, inflammation, and apoptosis after unilateral ureteral obstruction. *Kidney international* 2004; **66**(2):597-604.
30. Weiner DE, Tighiouart H, Elsayed EF, Griffith JL, m DN, Levey AS. Uric acid and incident kidney disease in the community. *American society of nephrology* 2008; **19**(6): 1204-1211.
31. Feig DI, Kang DH, Johnson RJ. Uric acid and cardiovascular risk. *New England journal of medicine* 2009; **359**(17): 1811-1821.
32. Atalay E, Korlaelci F, Gursoy G, Karabag Y, Yildiz M, Erdogdu HI, Kivrak Y. The possible effect of vitamin d on uric acid levels in diabetic patients. *World clinic journal medical sciences* 2017; **1**(2): 77-83.
33. Takir M, Solak Y, Erek A, Kostek O, Oral A, Elcioglu OC, Bakan A, Afsar B, Ozkok A, Jalal D, Johnson RJ, Bahat KA, Odabas AR, Kanbay M. Association between elevated serum uric acid and vitamin d insufficiency among the middle-aged and elderly population. *Turkish journal of nefrology* 2016; **25**(2):182-186.
34. Kono H, Chen C, Ontiveros F, Rock KL. Uric acid promotes an acute inflammatory response to sterile cell death in mice. *Journal of clinical investigation* 2010; **120**(6): 1939-1949.
35. Chen W, Roncal-Jimenez C, Lanaspa M, Smits G, Conchol M, Johnson RJ, Jalal D. Uric acid suppresses 1 alpha hydroxylase in vitro and *in vivo. Metabolism* 2014; **63**(1):150-160.
36. Roch-ramel F, Guisan B. Renal transport of urate in humans. *News in physiological science* 1999; **14**: 80-84.
37. Wynn TA, Vannella KM. Macrophages in tissue repair, regeneration, and fibrosis. *Immunity* 2016; **44**(3): 450-462.
38. Mirkovic K, Van Den Born J, Navis G, De Borst MH. Vitamin D in chronic kidney disease: new potential for intervention. *Current drug targets* 2011; **12**(1):42-53.
39. Ito I, Waku T, Aoki M, Abe R, Nagai Y, Watanabe T, Nakajima Y, Ohkido I, Yokoyama K, Miyachi H, Shimizu T, Murayama A, Kishimoto H, Nagasawa K, Yanagisawa J. A nonclassical vitamin D receptor pathway suppresses renal fibrosis. *Journal of clinical investigation* 2013; **123**(11): 4579-4594.
40. Li Y, Spataro BC, Yang J, Dai C, Liu Y. 1,25-dihydroxyvitamin D3 inhibits renal interstitial myofibroblast activation by inducing hepatocyte growth factor expression. *Kidney international* 2005; **68**(4): 1500-1510.
41. Yuan W, Pan W, Kong J, Zheng W, Szeto FL, Wong KE, Cohen R, Klopot A, Zhang Z, Li YC.1,25-Dihydroxyvitamin D3 suppresses renin gene transcription by blocking the activity of the cyclic AMP response element in the renin gene promoter. *Journal of biological chemistry* 2007; **282**(41): 29821-29830.
42. Corry DB, Eslami P, Yamamoto K, Nyby MD, Makino H, Tuck ML. Uric acid stimulates vascular smooth muscle cell proliferation and oxidative stress via the vascular renin – angiotensin system. *Hypertension* 2008; **26**(2): 269-275.
43. Makibayashi K, Tatematsu M, Hirata M, Fukushima N, Kusano K, Ohashi S, Abe H, Kuze K, Fukatsu A, Kita T, Doi T. A Vitamin D analog ameliorates glomerular injury on rat glomerulonephritis. *American journal of pathology* 2001; **158**(5): 1733-1741.
44. Arfian N, Ats-tsani HK, Sayekti PI, Lakabela DA, Amelia, Febriyanto T, Antonio HRP, Wibisono DP, Sari DCR. Prolonged kidney ischemia-reperfusion injury associates with inflammation, vascular remodelling, and myofibroblast formation. *Journal of medical science*

[Downloaded from ibj1.pasteur.ac.ir on 2026-10-17]
[DOR: 20.1001.1.1028852.2021.25.6.3.7]
[DOI: 10.52547/ibj.25.6.417]

2018; **50**: 1-14.
45. Brewster UC, Perazella MA. The renin-angiotensin-aldosterone system and the kidney : effects on kidney disease. *American journal of medical science* 2004; **116**(4): 263-72.
46. Ruster C, Wolf G. Renin-angiotensin-aldosterone system and progression of renal disease. *American society of nephrology* 2006; **17**(11): 2985-2991
47. Weiwei S, Guo L, Liu G, Peng T, Li H, Xie T, Dengren L, Zhen J, Wang Y, Yang H, Yang X. Protective effect of calcitriol on podocytes in spontaneously hypertensive rat. *Journal of Chinese medical association* 2018; **81**(8): 15691-698.
48. Klaus G. Renoprotection with vitamin D: specific for diabetic nephropathy? *Kidney international* 2008; **73(3)**: 141-1438.
49. Arfian N, Kusuma MHH, Anggorowati N, Nugroho DB, Jeffilano A, Suzuki Y, Ikeda K, Emoto N. Vitamin D upregulates endothelin-1, ETBR, eNOS mRNA expression and attenuates vascular remodelling and ischemia in kidney fibrosis model in mice. *Physiological research* 2018; **67(**Suppl 1): S137-S147.
50. Ramirez AM, Wongtrakool C, Welch T, Steinmeyer A, Roman J. Vitamin D inhibition of pro-fibrotic effects of transforming growth factor β1 in lung fibroblasts and epithelial cells. *Journal of steroid biochemistry and molecular biology* 2011; **118**(3): 142-150.
51. Finkel T, Holbrook NJ. Oxidants, oxidative stress, and the biology of ageing. *Nature* 2000; **408**(6809): 239-247.
52. Fridovich I. Superoxide dismutases. *Advances in enzymolology related areas of molecular biology* 1986; **58**: 61-97.
53. Merriman TR. An update on the genetic architecture of hyperuricemia and gout. *Arthritis research therapy* 2015; **17**(1): 98.
54. Desideri G, Gentile R, Antonosante A, Benedetti E, Grassi D, Cristiano L, Monocchio An, Selli S, Ippoliti R, Ferri C, Borghi C, Giordano A, Cimini A. Uric acid amplifies Aβamyloid effects involved in the cognitive dysfunction/dementia : evidences from an experimental model in vitro. *Journal of cellular physiology* 2017; **232**(5): 1069-1078.
55. Zhong W, Gu B, Gu Y, Groome LJ, Sun J, Wang Y. Activation of vitamin D receptor promotes VEGF and CuZn-SOD expression in endothelial cells. *Journal of steroid biochemistry and molecular biology* 2014; **140**: 56-62.
56. Hamden K, Carreau S, Jamoussi K, Ayadi F, Garmazi F, Mezgenni N, Elfeki A. Inhibitory effects of 1α25dihydroxyvitamin D3 and *Ajuga iva* extract on oxidative stress, toxicity, and hypo-fertility in diabetic rat testes. *Journal of physiology and biochemistry* 2008; **64**(3): 231-240.
57. Gren A. Effects of Vitamin E , C and D supplementation on inflammation and oxidative stress in streptozotocin-induced diabetic mice. *International journal for vitamim nutriton research* 2013; **83**(3): 9831.
58. Finch JL, Suarez EB, Husain K, Ferder L, Cardema MC, Glenn DJ, Gardner DG, Liapis H, Slatopolsky E. Effect of combining an ACE inhibitor and a VDR activator on glomerulosclerosis, proteinuria, and renal oxidative stress in uremic rats. *American journal of physiology-renal physiology* 2012; **302**(1): F141-F149.
59. Sezgin G, Ozturk G, Guney S, Orhun S, Tuncdemir M. Protective effect of melatonin and 1,25-dihydroxyvitamin D3 on renal ischemia–reperfusion injury in rats. *Renal failure* 2013; **35**(3): 374-379.
60. Izquierdo MJ, Cavia M, Muniz P,Francisco ALM, Arias M, Santos J, Abaigar P. Paricalcitol reduces oxidative stress and inflammation in hemodialysis patients. *BMC nephrology* 2012; **13**:159.

[Downloaded from ibj1.pasteur.ac.ir on 2026-10-17]
[DOR: 20.1001.1.1028852.2021.25.6.3.7]
[DOI: 10.52547/ibj.25.6.417]